

# Atlas of Gynecologic Surgery

Bearbeitet von  
Diethelm Wallwiener, Sven Becker

4th edition 2013. Buch. 676 p. Gebunden  
ISBN 978 3 13 650704 9  
Format (B x L): 270 x 310 cm

[Weitere Fachgebiete > Medizin > Klinische und Innere Medizin > Gynäkologie,  
Geburtshilfe, Materno-Fetal, Hebammen](#)

Zu [Inhaltsverzeichnis](#)

schnell und portofrei erhältlich bei

  
DIE FACHBUCHHANDLUNG

Die Online-Fachbuchhandlung [beck-shop.de](http://beck-shop.de) ist spezialisiert auf Fachbücher, insbesondere Recht, Steuern und Wirtschaft. Im Sortiment finden Sie alle Medien (Bücher, Zeitschriften, CDs, eBooks, etc.) aller Verlage. Ergänzt wird das Programm durch Services wie Neuerscheinungsdienst oder Zusammenstellungen von Büchern zu Sonderpreisen. Der Shop führt mehr als 8 Millionen Produkte.

# GYNECOLOGIC ONCOLOGY, UROGYNECOLOGY, PROCTOGYNECOLOGY: NEW SURGICAL TECHNIQUES

## 8.1 Exenterations

The strategy of curative exenteration signifies resection of all areas of tissue containing tumor, including the bladder, rectum, uterus, vagina, and also the vulva in the case of vulvar carcinoma. Exenteration may also be considered as a palliative procedure. The indications are tumor- or radiation-induced development of a cloaca and pronounced fistulation due to radiotherapy or tumor recurrence that cannot be managed surgically. Exenteration can also be reasonable in rare cases when malignancy is not confirmed histologically. The key questions when exenteration is considered are:

- ▶ To what extent will the procedure provide the patient with improved or at least qualitatively improved survival?
- ▶ Which reconstructive procedures should be employed as regards the rectum, vagina and bladder?

The important elements of different exenterative procedures are presented and discussed below.

### 8.1.1 Development of Evisceration Surgery

In more than a third of all uncured cervical carcinomas, the tumor remains limited to the pelvis until death. Patients die as a result of uremia, erosive hemorrhage, intestinal obstruction, or tumor cachexia. The fact that some squamous epithelial carcinomas only metastasize late led gynecologic oncologists at an early stage to develop “ultraradical” operation techniques. Such surgery requires great technical skill, intensive interdisciplinary collaboration, and optimized perioperative management in an intensive care unit (ICU).

Evisceration surgery was controversial for a long time, not only on account of its high morbidity and mortality rates but also because of the not inconsiderable mutilation of the patient. In recent years, evisceration surgery has experienced a renaissance with the introduction of appropriate reconstructive procedures such as low coloanal anastomosis, the development of largely continent neobladders, and reconstruction of the vagina. Provided the decision is made with care, this “ultraradical” surgery can therefore be accepted as an individual solution in otherwise desperate cases. The mortality has been reduced to a few per cent. Major postoperative complications have become much less frequent as a result of various technical modifications of the surgery and greater surgical experience.

### 8.1.2 Indications and Contraindications

#### Indications

For the gynecologic oncologist, the question of evisceration surgery arises primarily in the case of recurrent cervical and vaginal carcinoma and advanced vulvar malignancies. These tumors tend to be rather slowly growing squamous epithelial cancers that infiltrate by continuity. There is consensus that this procedure may be considered especially when there is still a good chance of cure (curative exenteration). However, performing it in palliative situations where nursing is becoming impossible may also be justifiable, especially when radiation therapy or polychemotherapy is no longer an alternative. The indications for pelvic evisceration can be:

- ▶ Persistent or recurrent cervical or vaginal carcinoma or advanced vulvar malignancy. Squamous epithelial carcinomas respond markedly better to the exenterative approach than adenocarcinomas. Some authors regard adenocarcinoma as a relative contraindication because of its earlier hematogenous metastasis, while other authors report long-term survival rates of up to 50% in selected patients. The strict correlation between the time to first recurrence and the chance of survival following exenteration should be mentioned here.
- ▶ Other recurrent or unsuccessfully treated malignancies of pelvic organs such as carcinoma or sarcoma of the uterus, vagina, rectum, bladder, or vulva. Ovarian carcinoma is not suitable for exenteration in the classic sense because of its completely different tumor biology. Although typical ovarian carcinoma surgery is often tantamount to posterior exenteration, the microscopic R0 situation does not play the same role.
- ▶ Incurable fistulas and/or extensive radiation fibrosis in the pelvis in exceptional cases. The complications of evisceration surgery are particularly high in these indications. In patients with a vesicovaginal and/or rectovaginal fistula alone without concomitant local recurrence, the emphasis is on urinary and fecal diversion procedures.

## Contraindications

The contraindications can be of a general or local nature.

**General contraindications.** General reasons against performing such surgery include: poor general condition, advanced age, mental or physical difficulties in adapting to the operation and its consequences, significant renal damage with incipient uremia, and, in particular, extrapelvic metastasis. The latter must be excluded preoperatively (chest radiograph, isotope bone scan, upper abdominal ultrasonography, CT, MRI, which is particularly important in assessing soft tissue infiltration, PET-CT if appropriate, and sometimes scalene biopsy).

**Local contraindications.** The local contraindications to pelvic evisceration are: carcinoma infiltrating the pelvic skeleton (hemipelvectomy is rejected today) and tumor infiltration in the region of the sciatic foramen with sciatica or leg edema. In many cases, the question of operability can be decided only during laparotomy. Unless indications are strictly followed, it is impossible to achieve acceptable morbidity and mortality risks and also acceptable cure rates. The most important contraindication is the preoperative certainty that the tumor-containing tissue cannot be resected with a margin of healthy tissue. In this situation the structures of the pelvic wall are infiltrated directly (see also p. 606, Limits of the Method). The significance of positive pelvic lymph nodes is unclear. The 5-year survival rates range between 0% and 20% for exenteration with positive pelvic lymph nodes compared with 20%–70% when the pelvic lymph nodes are negative, with the best survival figures coming from the more recent operation series. Other important additional contraindications, which can be established only during surgery, are positive peritoneal cytology, macroscopic or microscopic intraperitoneal metastasis, and positive para-aortic lymph nodes.

## 8.1.3 Problems of Operation Technique

Improvements in evisceration operation techniques have been important factors in reducing morbidity and mortality. The following problems merit discussion:

**Choice of operation procedure.** In about three-quarters of cases, total pelvic evisceration is the method of choice. By contrast, partial pelvic eviscerations require a clear indication. The wish for an intact intestinal or urinary tract should not lead to a less radical procedure if the chances of cure are worsened as a result. Posterior exenteration in particular is problematic because of the complete bladder denervation.

**Lining the wound cavity in the pelvis.** In recent years, two procedures in particular have become accepted: lining the pelvic cavity with a pedicled omental flap or—less widely done—with a free or pedicled flap of peritoneum. The omental flap offers the advantage of an intact blood supply, which can be important especially following radiation. On the other hand, lining the pelvis with peritoneum is simpler because the appropriate tissue is always available.

**Drainage.** The use of closed drainage systems with or without suction is standard nowadays and is rational especially in extensive operations with large wound cavities.

**Urinary conduits.** Continent pouches such as the Miami pouch or Mainz-I pouch are the first choice today for urine drainage, but they are technically elaborate and the surgery cannot be done everywhere. Intestinal conduits are available as an alternative, but these are only a second choice.

**Lymphadenectomy.** If this is a primary procedure without previous lymphadenectomy, the initial step is para-aortic lymphadenectomy. Further planning is dependent on the result of the frozen section. The result of pelvic lymphadenectomy does not influence the planned procedure to the same extent as the status of the para-aortic lymph nodes. Particularly in previously irradiated areas, lymphadenectomy is associated with high intraoperative risk (vascular injury) and high postoperative risk (lymphedema). Selective pelvic or para-aortic lymphadenectomy is indicated in any case if metastasis in this area is suspected.

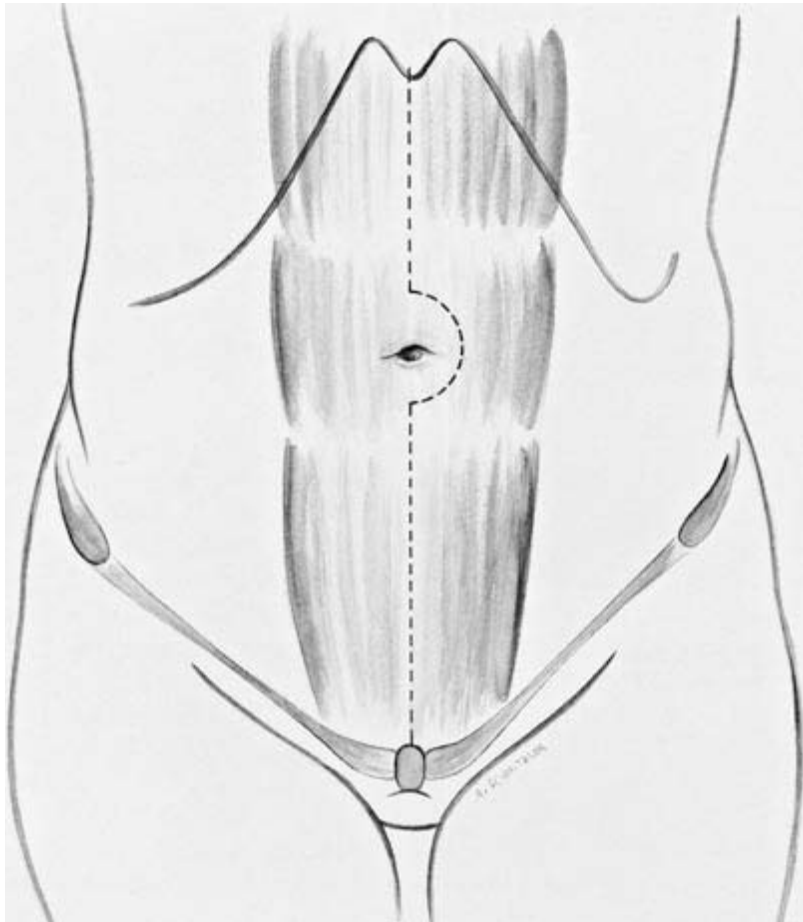
## 8.1.4 Errors and Failures

**Selection of unsuitable patients.** Failures are due especially to selecting unsuitable patients. With good preoperative investigations, 50%–65% of all patients are (technically) operable at laparotomy. CT and MRI should be used to rule out metastases and assess local infiltration preoperatively, though the low sensitivity of the two methods should be borne in mind. Whether the patient is operable can often be determined only at operation, which represents a severe psychological burden for a patient who proves ultimately to be inoperable.

**Other causes.** Another cause for a poor final result is an incorrect operative procedure. Choosing too conservative an operative procedure can also be a cause of failures. Finally, technical errors during such extensive procedures often lead to increased morbidity and mortality. Postoperative management is crucial. Modern surgical and anesthesiologic ICUs and better monitoring overall have largely solved this problem.

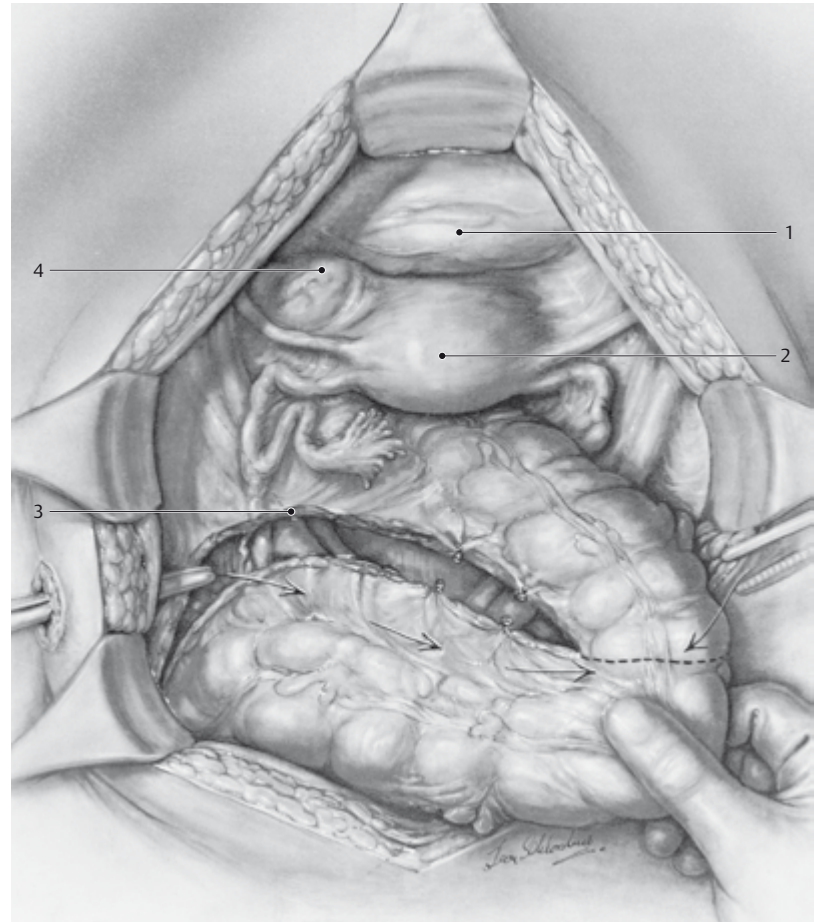
## 8.1.5 Operation Procedures

### Starting the Operation and Preparation for Exenteration



**Fig. 8-1-1 Midline laparotomy.** Only a few surgeons still prefer the transverse approach. The operation starts by opening the abdominal cavity, usually followed, in the case of reoperation, by more or less extensive division of adhesions to reconstruct a normal anatomy. As soon as possible, all peritoneal surfaces in the upper, middle, and lower abdomen are inspected and

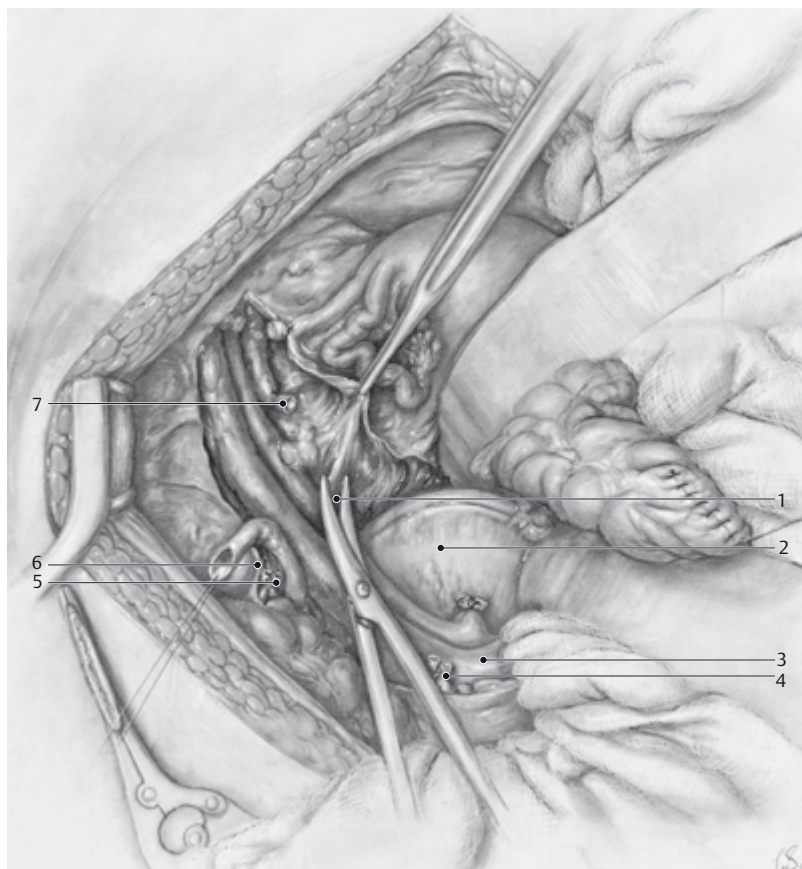
the abdominal cavity, liver, spleen, the root of the mesentery, and the bed of the pancreas are explored by palpation. Abnormal areas are biopsied and the material obtained is sent for frozen section. Involvement of peritoneal structures is regarded as a contraindication to exenteration.



**Fig. 8-1-2** The pelvis is assessed. The para-aortic lymph node region should be assessed first as the overall indication must be reconsidered if these lymph nodes are affected. The next steps serve to prepare for the exenteration. Mobilization of the rectosigmoid is shown. On the one hand, the posterior part of the exenteration is prepared and on the other, this provides free access to the left pelvic wall, to the left-

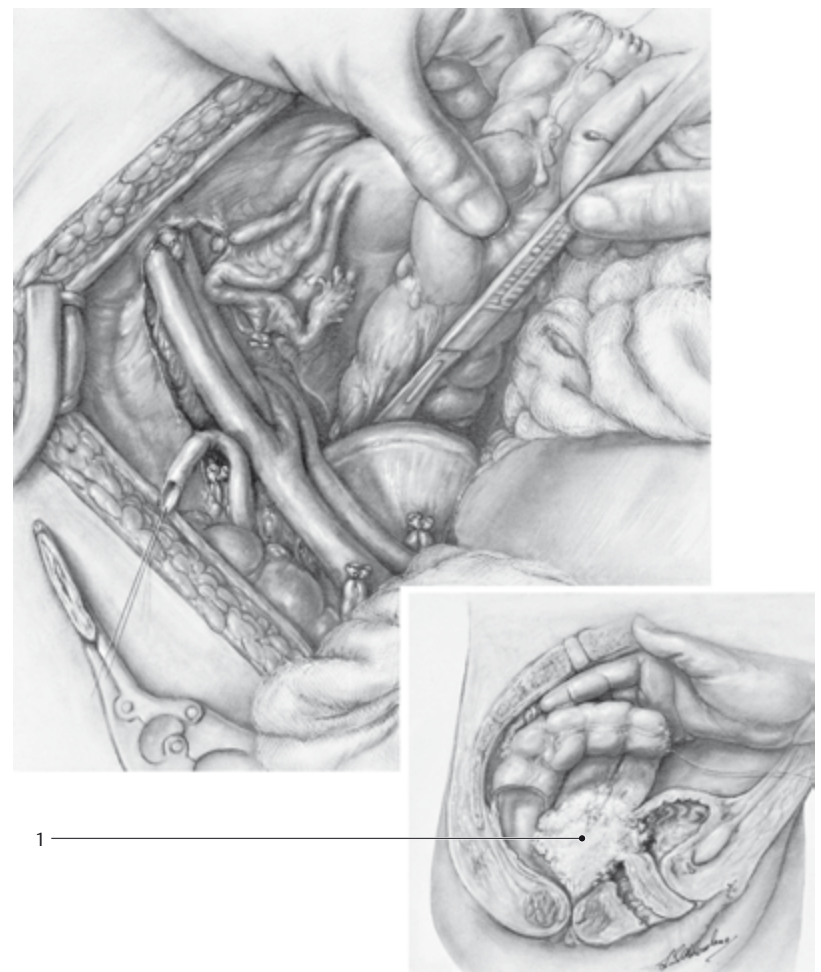
sided pelvic lymph nodes if necessary, and in particular to the course of the left ureter. The colon also has to be mobilized for reconstructive procedures (neovagina, neobladder). Pelvic lymphadenectomy, which should at least exclude multiple involvement, and assessment of local resectability are the next steps; 1 = bladder, 2 = uterus, 3 = incision of the sigmoid mesocolon, 4 = tumor.





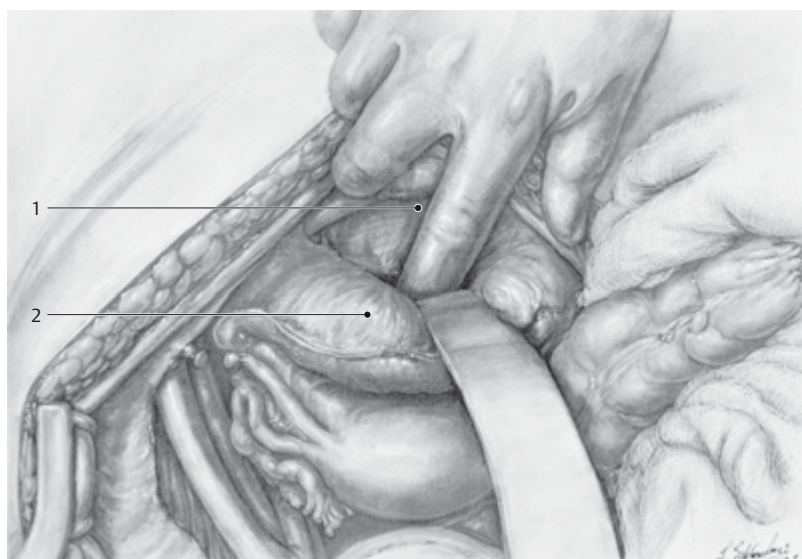
**Fig. 8-1-3** Exposure of the left wall of the pelvis. The pelvic walls must be exposed on both sides by a combination of blunt and sharp dissection before the actual exenteration begins. Exenteration should only be considered when an operation plane toward the pelvic wall can be guaranteed, if necessary with the aid of intraoperative biopsies and frozen section histopathology. If the para-aortic lymph nodes are negative, pelvic lymphadenectomy should be performed unless fibrosis due to radiation makes this step appear too risky (not least with regard to the development of lymphedema in the long term). The ureters must be ex-

posed completely on both sides and divided relatively early in the operation (7). The perivesical and perirectal spaces are dissected in the classic manner. The internal iliac artery should be dissected completely so that it can be ligated in situations of extreme bleeding; 1 = dissection of the fat and connective tissue containing lymph nodes from the external iliac vessels, 2 = promontory, 3 = bifurcation of the aorta, 4 = stumps of the superior rectal arteries and veins, 5 = divided ovarian vessels, 6 = incision of the peritoneum along the iliac vessels.



**Fig. 8-1-4** Inspection of the tumor (1), assessment of local central infiltration of the rectum and bladder, and finally start of the actual exenteration are shown. Depending on the operation plan (total exenteration, anterior or poste-

rior exenteration), the previously begun dissection of the rectosigmoid is continued. The rectum is mobilized and freed from the sacrum largely by blunt dissection, with sharp dissection in the region of the uterosacral ligaments.



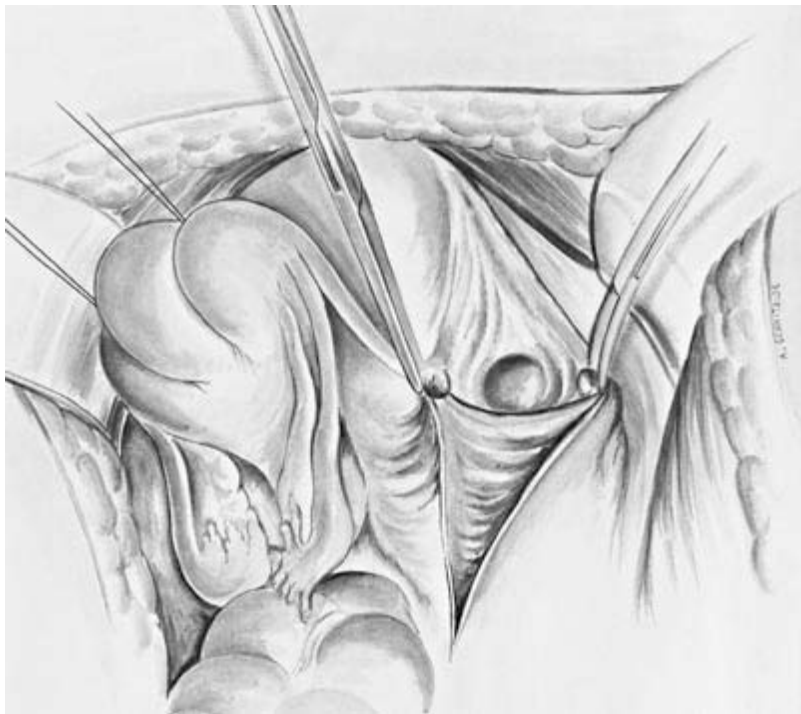
**Fig. 8-1-5** Dissection for total exenteration in the anterior compartment of the pelvis starts by separating the bladder (2) from the symphysis (1). As soon as exenteration has been decided on (negative para-aortic lymph nodes, largely negative pelvic lymph nodes, resection feasible as far as the pelvic wall), it is advisable to complete exposure of the pelvic walls by ligating the visceral blood supply: the uterine artery is ligated at its origin from the internal iliac artery, the umbilical artery is divided, and the su-

perior vesical artery is ligated. By proceeding bilaterally, the continuous blood loss from the central tumor-bearing area is less and dissection is correspondingly easier. Some authors advocate ligation of the internal iliac artery directly after it is crossed by the internal iliac vein. This means ligation of the uterine artery, superior vesical artery, and umbilical artery, while the internal pudendal artery (with the terminal branches of the inferior rectal artery) and the obturator artery are spared.

## Anterior Exenteration

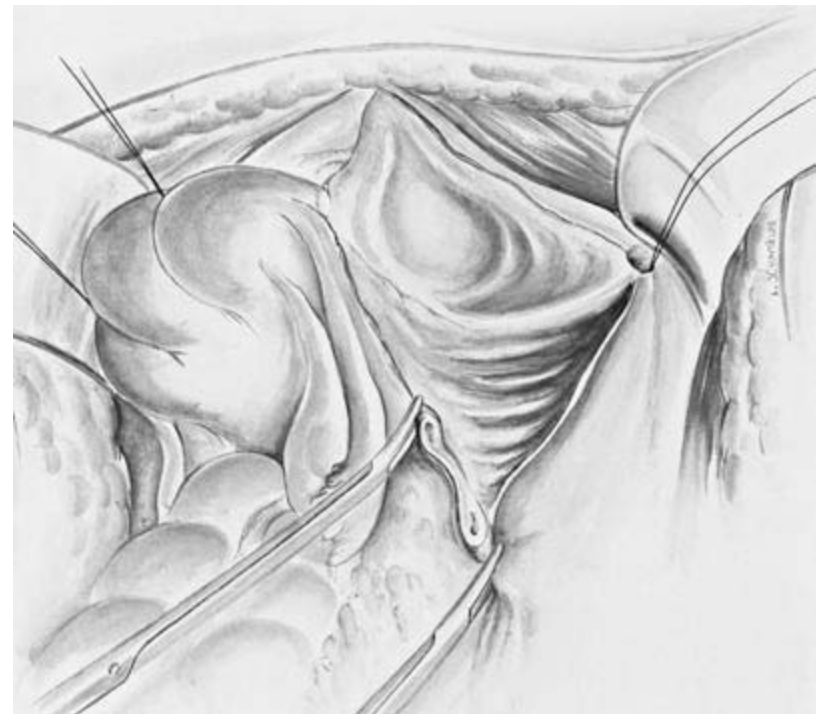Only examples of exenteration procedures can be described here as, like typical ovarian cancer surgery, they are highly individualized. Anterior exenteration is described below to illustrate the systematic approach to the actual steps of exenteration. As preoperative diagnostic imaging cannot adequately assess operability, explorative laparotomy is the final arbiter. In large series, an inoperable situation is still found in 30% of patients. Bowel mobilization, which is always necessary for exenteration, is not illustrated. This is in fact done in preparation for the reconstructive phase, during which, for instance, continent urine diversion and possibly a neovagina are constructed from the colon.

1. The paravesical space is opened bluntly to assess operability.
2. The round ligaments are ligated close to the pelvic wall.
3. The infundibulopelvic ligaments are ligated superior to the site where the (ovarian) vessels cross.
4. The ureters are exposed (with vessel loops).
5. Lymphadenectomy is performed.
6. The umbilical artery and superior vesical artery are divided.
7. The superior vesicouterine ligaments are divided.
8. The ureters are resected (with frozen section).
9. The uterine artery and vein are divided close to the pelvic wall (with frozen section).
10. The internal iliac artery and vein are ligated distal to the origin of the superior gluteal artery.
11. The uterosacral ligaments are divided and ligated gradually as far as the paracolpium 5 cm distal to the cervix (with frozen section) and the paracolpium is suture ligated.
12. The retrosymphyseal space is opened.
13. The pubovesical ligaments are divided.
14. The deep dorsal vein of the clitoris is sutured.
15. The urethrovaginal septum is dissected as far as the external urethral meatus.
16. Colpectomy and start of the reconstructive phase.



**Fig. 8-1-6** Every pelvic manipulation should be preceded by histopathological evaluation of the para-aortic lymph nodes. If the para-aortic and para-caval lymph nodes below the origin of the inferior mesenteric artery are negative, metastasis beyond them ("skip metastasis") is not to be expected with squamous epithelial carcinomas. The next step is dissection of the pelvic wall, which follows the general principles of gynecologic cancer surgery when the inter-

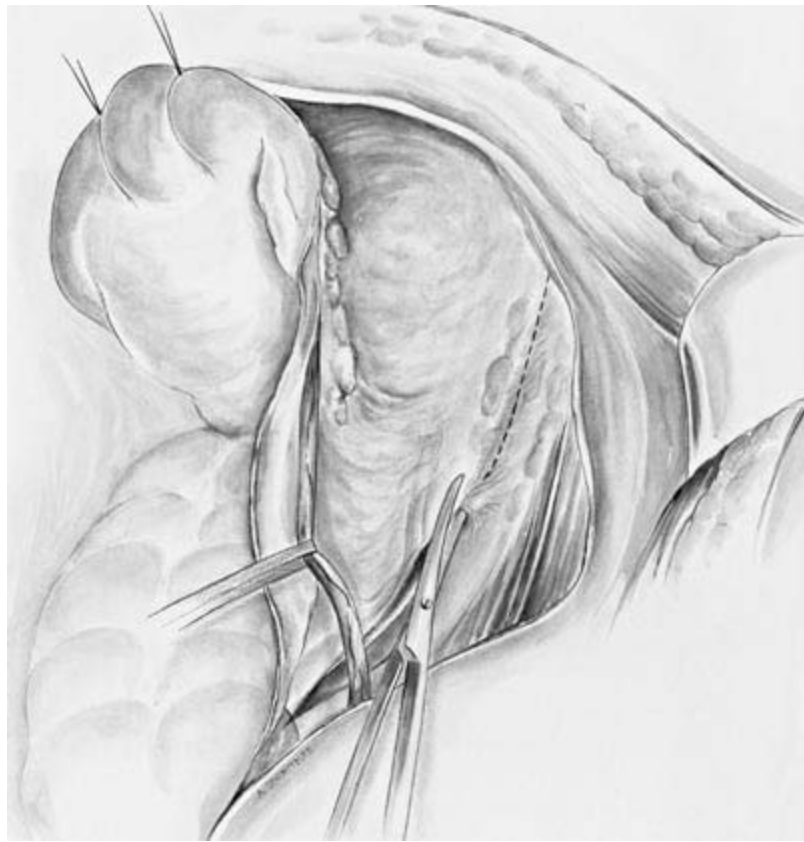nal genitalia are intact. The illustration shows division of the round ligament. Alternatively—and this is usually better—the retroperitoneum is entered through the psoas muscle with immediate exposure of the external and then the internal iliac vessels, the iliac bifurcation, and the ureter crossing it, which is dissected free, separated from the infundibulopelvic ligament, and marked with a soft silicon tape.



**Fig. 8-1-7** After opening the abdominal cavity and following adhesiolysis as necessary to reconstruct the normal anatomy, systematic inspection and palpation are important; these must gradually answer the questions that arise before the actual exenteration is performed: Are there distant metastases? Is there peritoneal penetration or peritoneal metastasis? Para-aortic lymphadenectomy should always precede the exenteration, if appropriate after

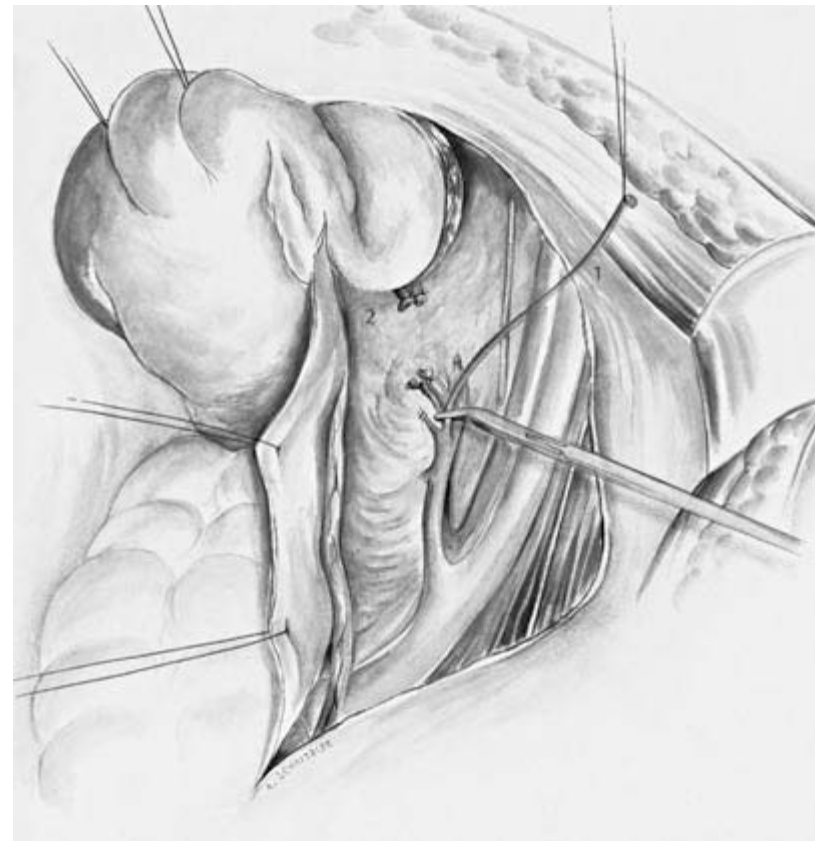
a positive assessment of local resectability. The adnexa are usually not preserved in an exenterative procedure. With cervical carcinoma, large tumors (>4 cm) are usually present, and the rate of metastasis to the adnexa increases markedly even with squamous epithelium-like histology. The illustration shows division of the infundibulopelvic ligament. Placing retaining sutures around the uterus is obsolete in oncology. Straight clamps are appropriate.





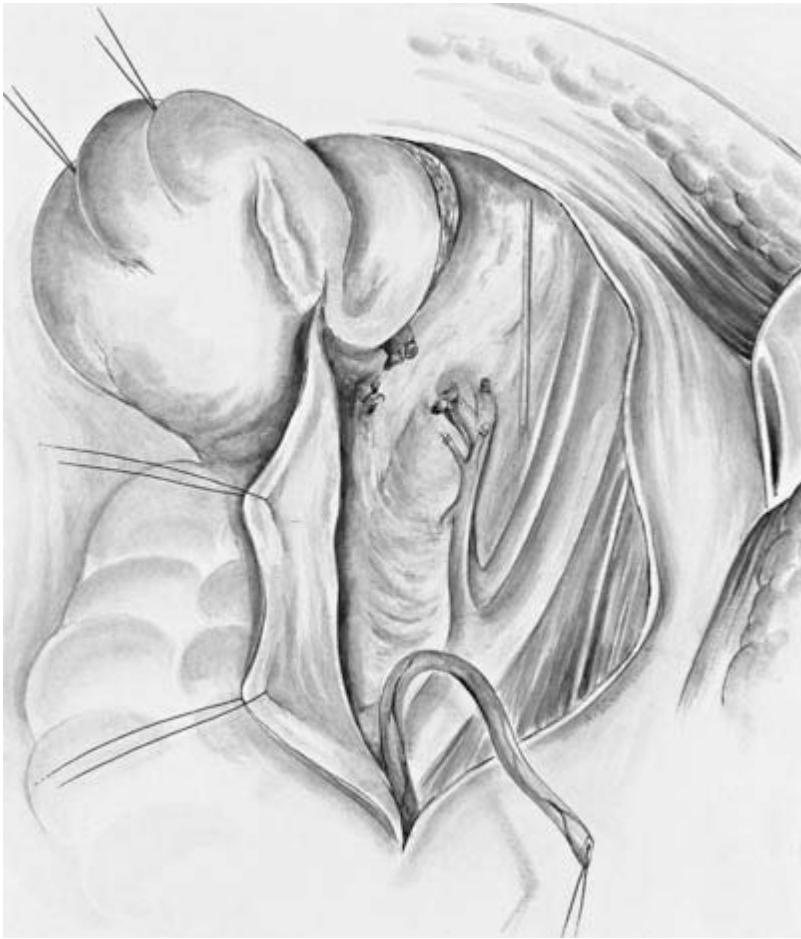**Fig. 8-1-8** The start of pelvic lymphadenectomy with the right ureter retracted. Resectability with regard to the pelvic wall is initially assessed by rectovaginal examination under anesthesia, then by palpation within the abdomen, and finally after exposure of the pelvic wall, which at the same time provides access for pelvic lymphadenectomy. Pelvic lymphadenectomy is obligatory in the event of the rare primary exenteration, though opinions regarding the consequences diverge, unlike the situation when the para-aortic lymph nodes are affected. The prognosis following exenteration is worse

when the pelvic lymph nodes are positive (5-year survival rate 0%–20% compared with 50%–80% when the pelvic lymph nodes are negative), but the surgeon must decide on an individual basis, especially when isolated lymph nodes are affected. Removal of pelvic lymph nodes is more problematic after radiation. The classic lymphadenectomy area often lies directly in the area of radiation-induced fibrosis. Injuries of the obturator nerve and iliac veins are a major hazard. A risk–benefit assessment is necessary in the individual case.



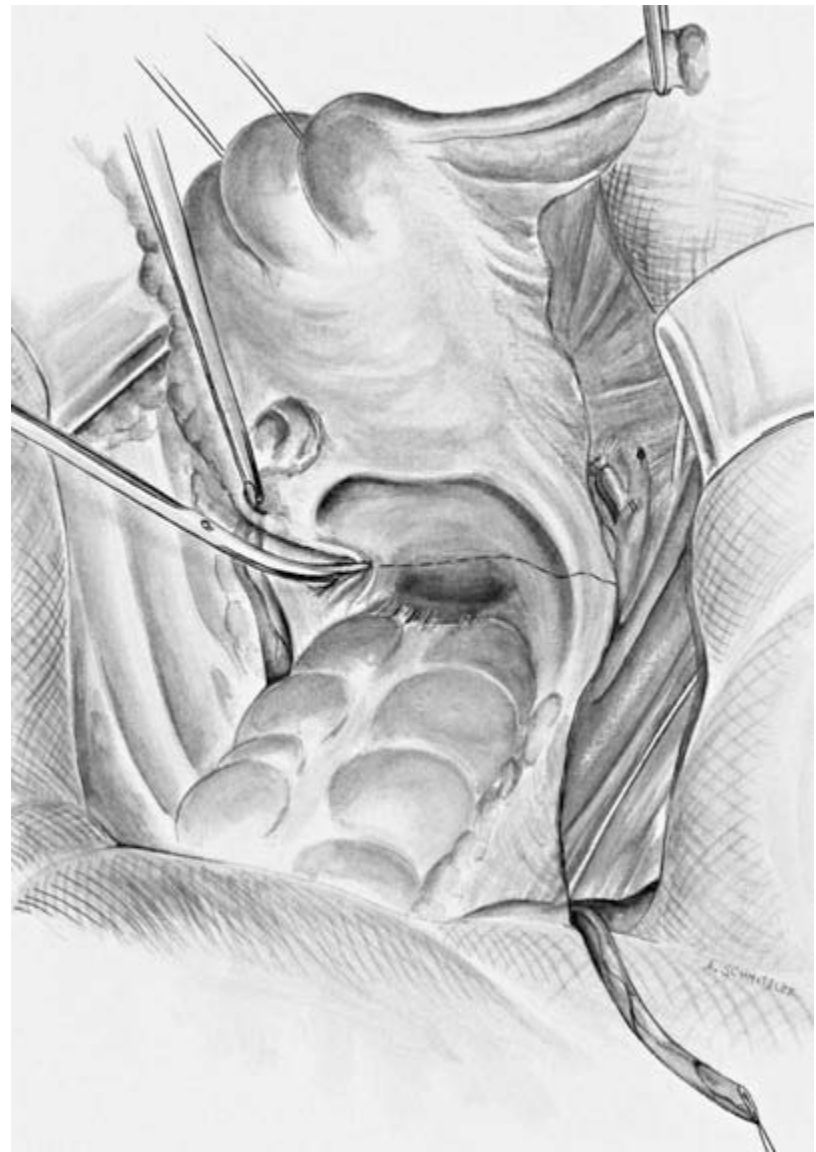
**Fig. 8-1-9** Pelvic lymphadenectomy is concluded. Various approaches are possible. A Piver III procedure can be performed in principle, similar to radical hysterectomy, but the line of division of the pelvic tissue is directly on the wall of the pelvis (Piver IV). Some authors recommend ligation of the internal iliac artery directly after it crosses the internal iliac vein, though this crossing point is not always clearly defined when the vessel runs tangentially. The

uterine artery, superior vesical artery and umbilical artery, also called the lateral umbilical ligament, must be ligated securely in one way or another. Extremely distal ligation of the obliterated umbilical artery is shown here (1). The superior vesical artery is also divided and ligated (2). Retraction of the peritoneum and of the uterus by retaining sutures is practiced by only a few authors.



**Fig. 8-1-10** The ureter is divided as distally as possible oncologically before it enters the bladder and a retaining suture is placed at 6 o'clock. Frozen section of the distal ureter to confirm R0 status is recommended. Some authors ligate the ureter distally, which then distends in the course of the operation, facilitating reimplantation during the reconstructive phase. The parametria with the uterine artery and vein are divided into two portions. The lateral resection margins must be examined by multiple intraop-

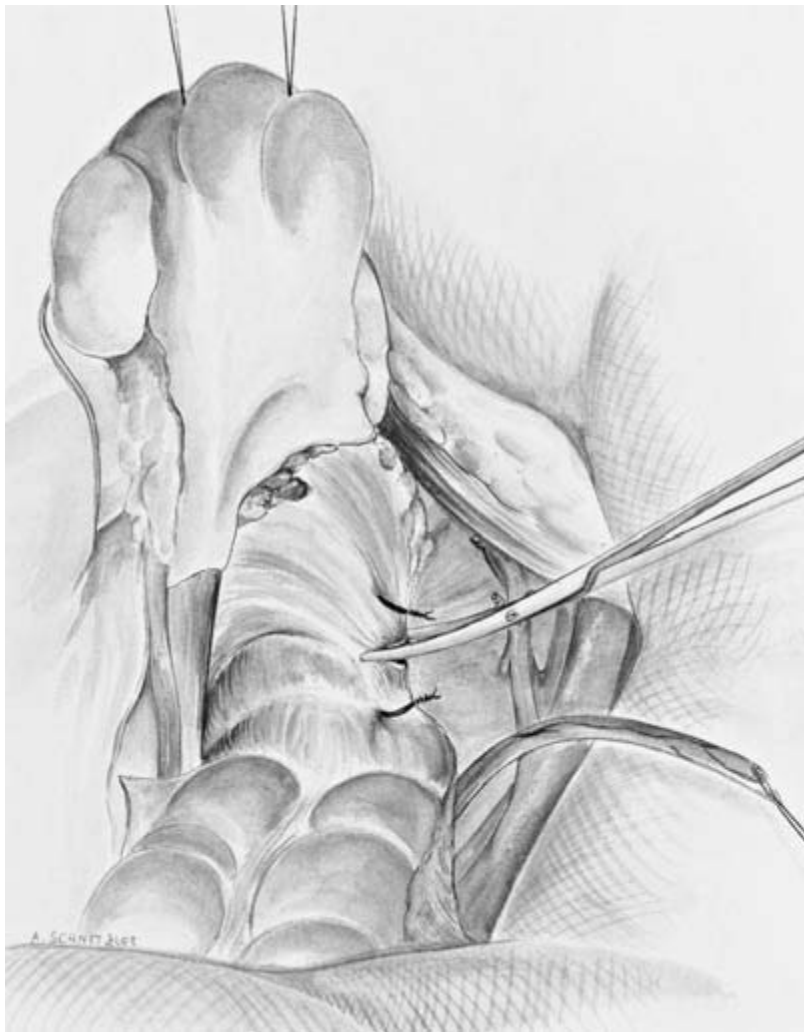erative biopsies and frozen sections to ensure that they are tumor-free. Unlike what is shown here, preservation of the obturator artery can be beneficial, as the gracilis muscle, which is important for reconstructive procedures, is supplied by terminal branches of the obturator artery. In any case, the internal iliac artery should not be ligated proximal to the origin of the so-called posterior trunk, which includes the superior gluteal artery.



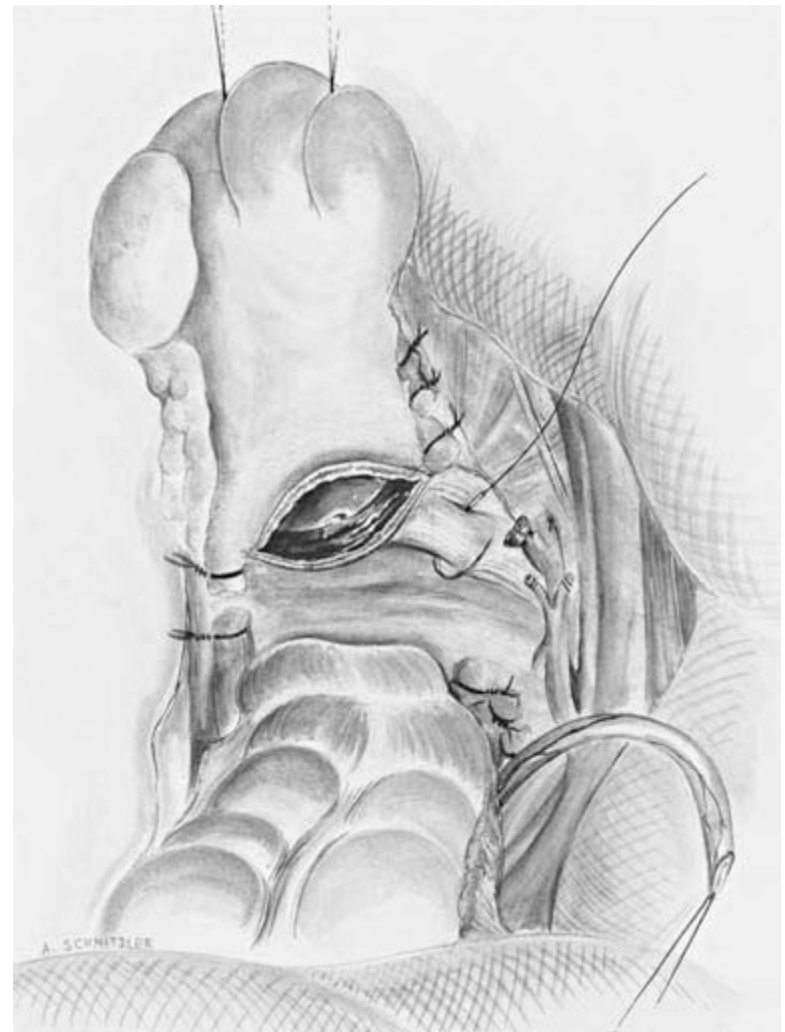
**Fig. 8-1-11** In anterior exenteration the rectosigmoid does not have to be removed. Hysterectomy is performed in posterior direction, corresponding to Piver III radical hysterectomy, replacing the nerve-sparing resection of the uterosacral ligaments by extensive resection in favor of wide tumor-free dissection margins, as the bladder is removed anyway as part of the specimen. Opening the peritoneum of the pouch of Douglas is crucial for dissection of

the rectovaginal space. It has to be opened down to the perineum. Here, too, it is necessary to assess at operation whether the original plan of anterior exenteration is feasible on condition that tumor-free dissection margins are obtained or whether the rectosigmoid has to be removed as well. The final aim of anterior exenteration, besides pelvic lymphadenectomy, is removal of the bladder, urethra, uterus, ovaries, and vagina.

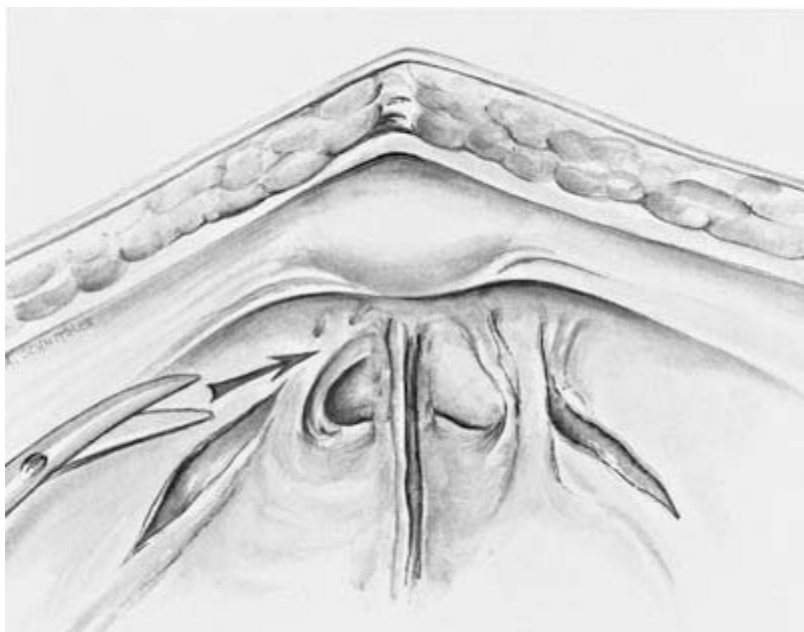




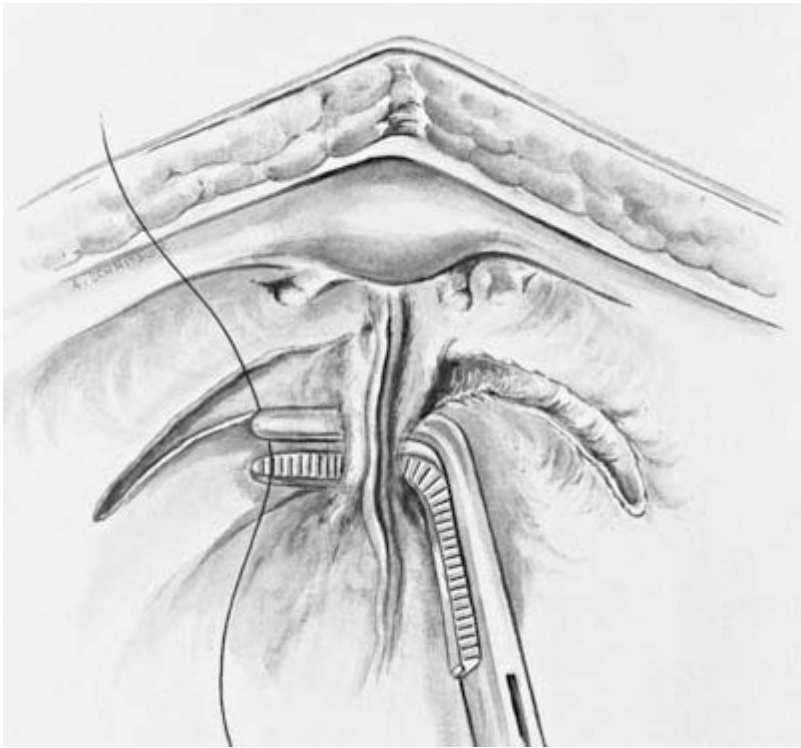
**Fig. 8-1-12** Gradual division of the uterosacral ligaments close to the rectum conventionally over clamps as far as the parts of the paracolpium that meet them at a right angle (see also p. 235—anterior exenteration is in principle a Piver III operation, adapted to the extent of the tumor, though the ureters do not have to be taken into account).



**Fig. 8-1-13** The vagina is opened transversely distal to the cervix and the paracolpium is suture ligated laterally, observing the desired R0 status. Although anterior exenteration is a classical gynecologic oncology procedure, it is also performed in urology in association with bladder and urethral carcinomas.

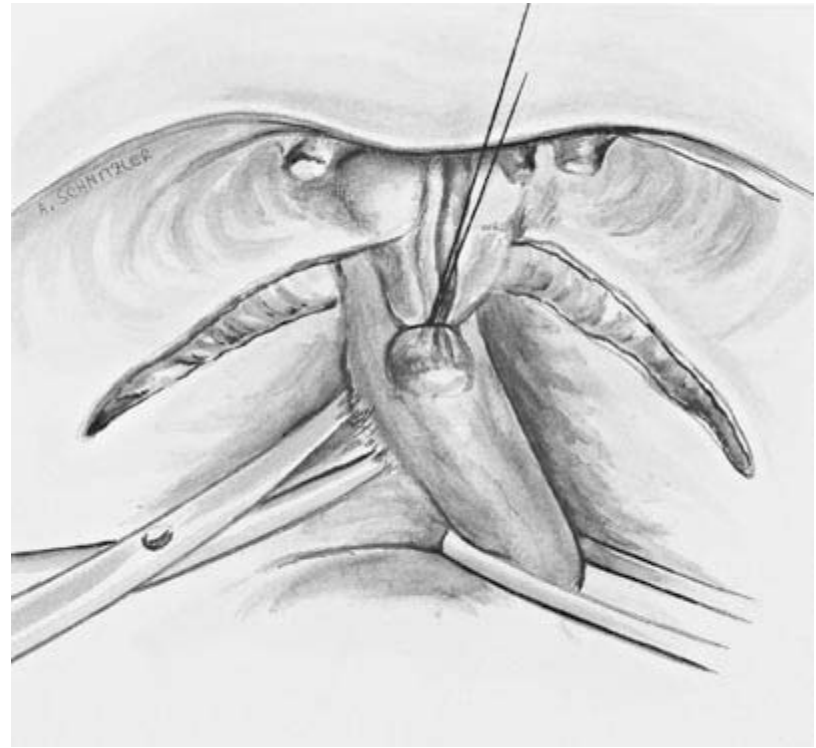


**Fig. 8-1-14** After posterior dissection and opening of the vagina, attention turns to the anterior dissection and thus to the actual cystectomy. The pubovesical ligaments are exposed and divided bilaterally. Anterior dissection is continued by incising the endopelvic fascia further and dividing the pubourethral ligaments. These ligaments are avascular and can be dissected sharply or by means of electrocoagulation.



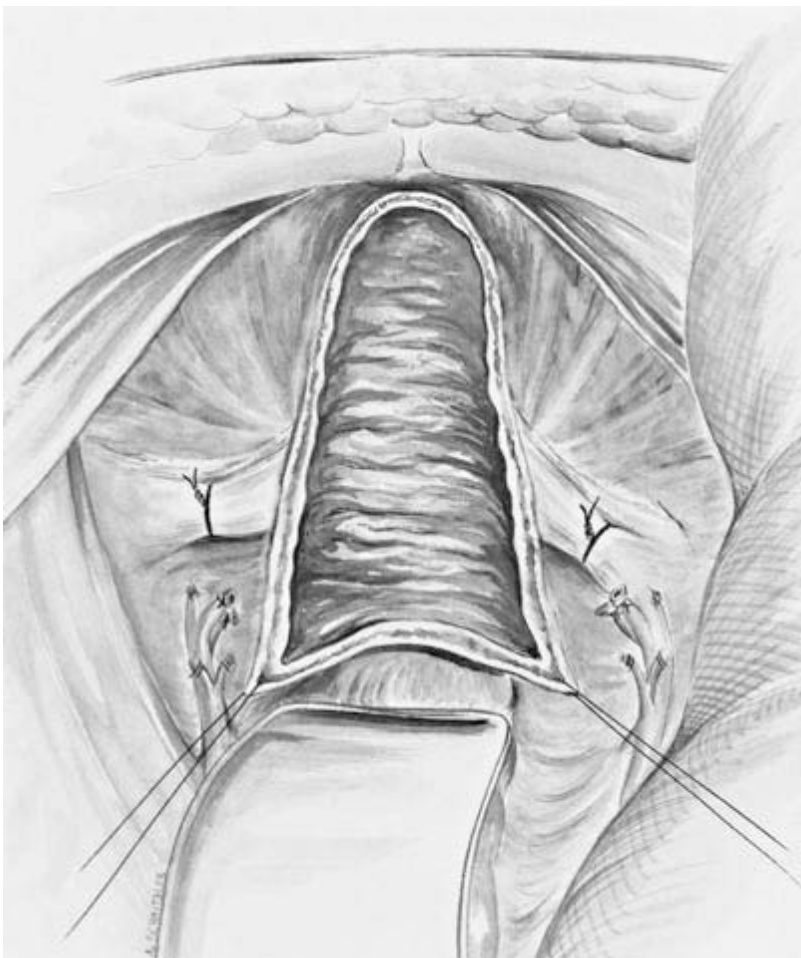**Fig. 8-1-15** The entire clitoral venous plexus is ligated. The palpable bladder catheter acts as a guide, with posterior and periurethral dissection along it. In the case of carcinomas close to the trigone and infiltrating the wall, the urethral meatus is resected together with a cuff of the

anterior vaginal wall. Intraoperative frozen sections from the following areas are required for adequately radical surgery: pelvic floor, cardinal ligaments or parametrium, uterosacral ligaments, ureter resection margin, vaginal resection margin, and paracolpium.



**Fig. 8-1-16** Mobilization of the urethra, which is also divided and ligated. Considerable venous bleeding can occur in the retropubic space, which is familiar to the gynecologic surgeon especially from urinary incontinence procedures.

After dividing the urethra, the bladder is mobilized and resected laterally with a combination of blunt and sharp dissection.



**Fig. 8-1-17** The operation site after removal of the specimen with resection of the anterior vaginal wall. In anterior exenteration because of gynecologic malignancy, partial or total colectomy is often necessary, which requires vaginal reconstruction, depending on the extent and overall situation. If appreciable parts of the posterior vaginal wall can be preserved (obtain frozen sections), these can be dissected free and reflected anteriorly to provide a slightly shortened reconstruction of the anterior

vaginal wall. If this is not sufficient, immediate vaginal reconstruction from the sigmoid colon or one of the other neovagina variants must be considered. Simultaneous fashioning of a continent neobladder can be problematic; this is usually constructed from the cecum and ascending colon. At the end of the operation, the pelvic wound cavity is filled with a previously mobilized greater omentum flap (omental plug).