

Anatomy

A Photographic Atlas

Bearbeitet von
Johannes W. Rohen, Chihiro Yokochi, Elke Lütjen-Drecoll

8 2015. Taschenbuch. 560 S. Paperback
ISBN 978 3 7945 2982 7
Format (B x L): 21 x 29,7 cm
Gewicht: 2300 g

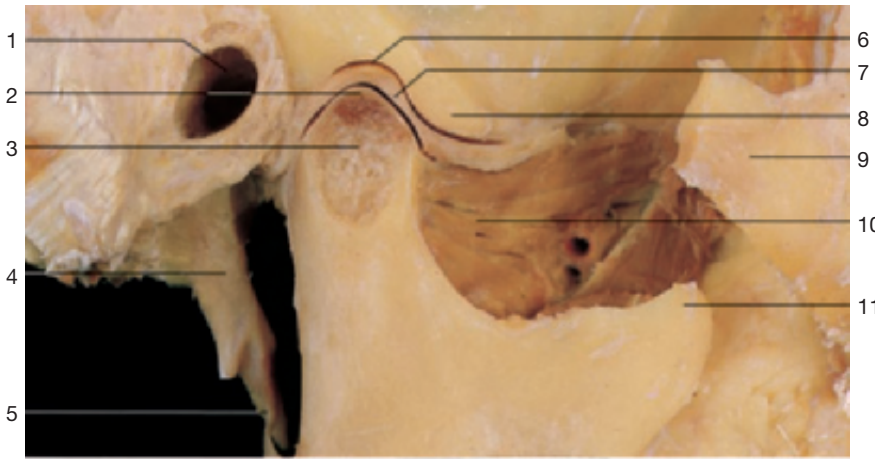
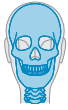[Weitere Fachgebiete > Medizin > Vorklinische Medizin: Grundlagenfächer > Anatomie](#)

Zu [Inhaltsverzeichnis](#)

schnell und portofrei erhältlich bei

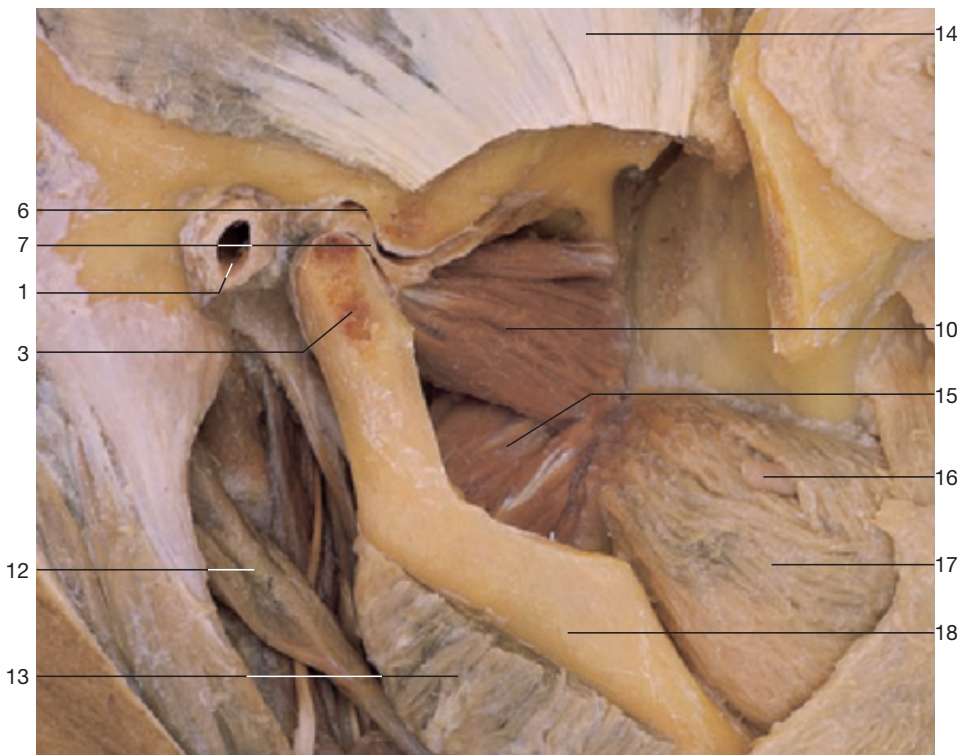
DIE FACHBUCHHANDLUNG

Die Online-Fachbuchhandlung [beck-shop.de](#) ist spezialisiert auf Fachbücher, insbesondere Recht, Steuern und Wirtschaft. Im Sortiment finden Sie alle Medien (Bücher, Zeitschriften, CDs, eBooks, etc.) aller Verlage. Ergänzt wird das Programm durch Services wie Neuerscheinungsdienst oder Zusammenstellungen von Büchern zu Sonderpreisen. Der Shop führt mehr als 8 Millionen Produkte.

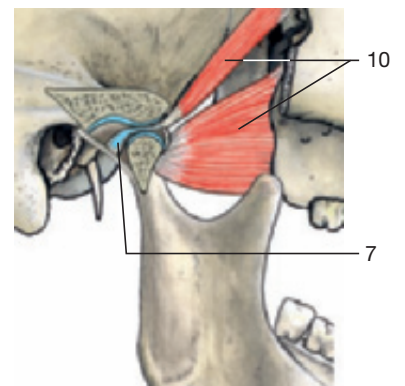
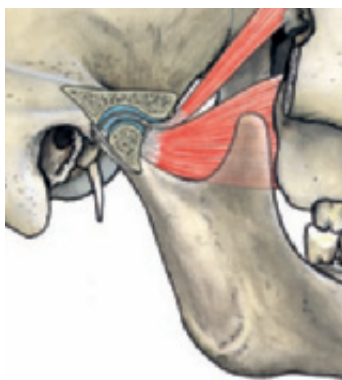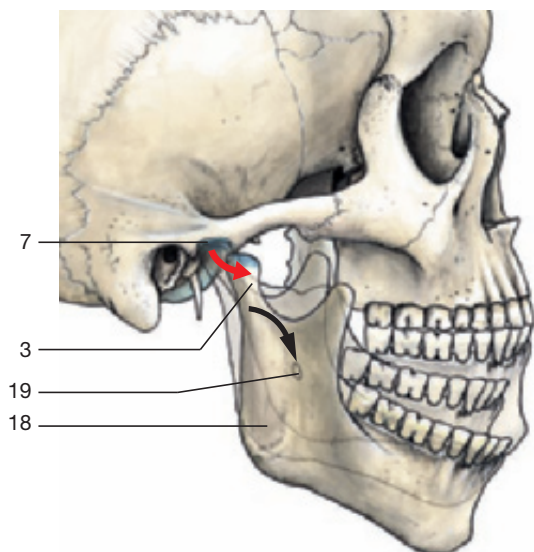


- 1 External acoustic meatus
- 2 Articular cartilage of condylar process
- 3 Condylar process of mandible
- 4 Styloid process
- 5 Stylomandibular ligament
- 6 Mandibular fossa
- 7 Articular disc
- 8 Articular tubercle
- 9 Zygomatic bone
- 10 Lateral pterygoid muscle
- 11 Coronoid process of mandible

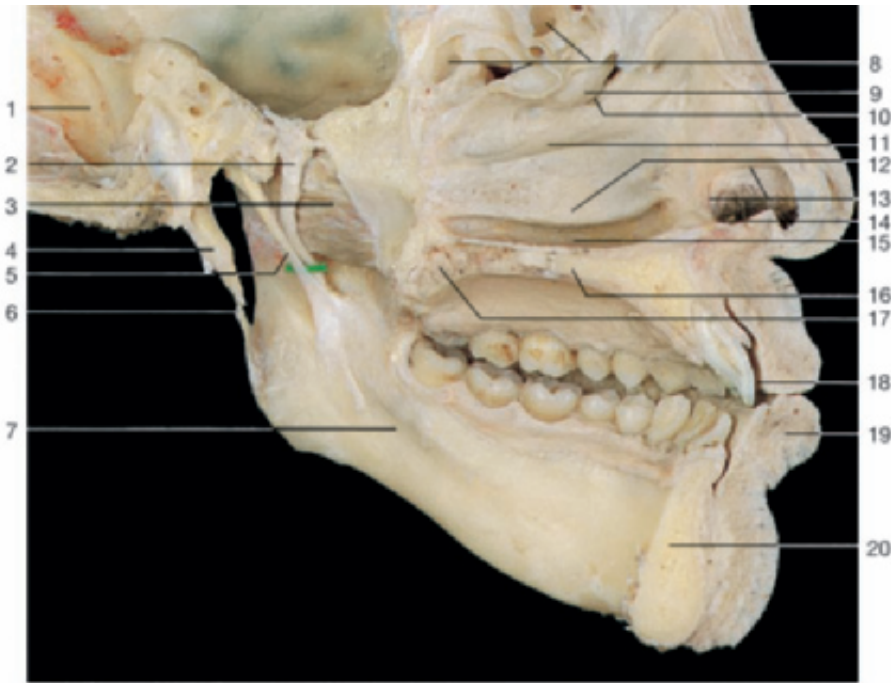
Temporomandibular joint (sagittal section).



Temporomandibular joint. Dissection of the articular disc and the related muscles (lateral aspect).

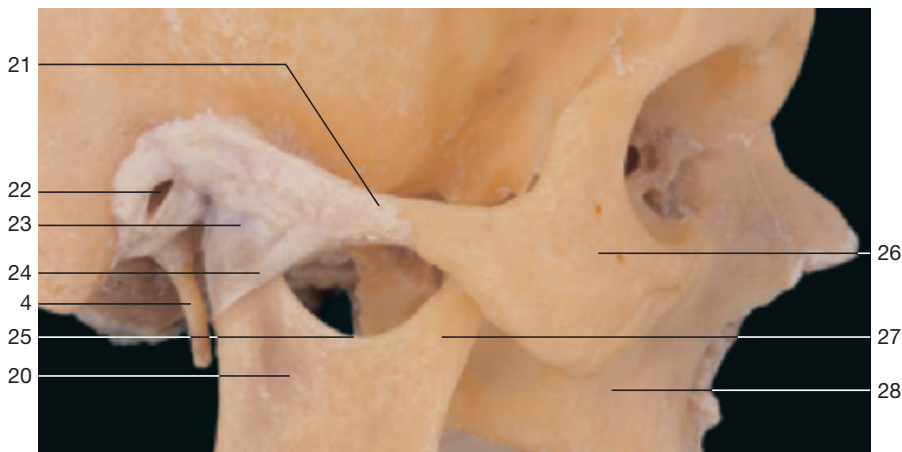

Movements of the temporomandibular joint and the related lateral pterygoid muscles.

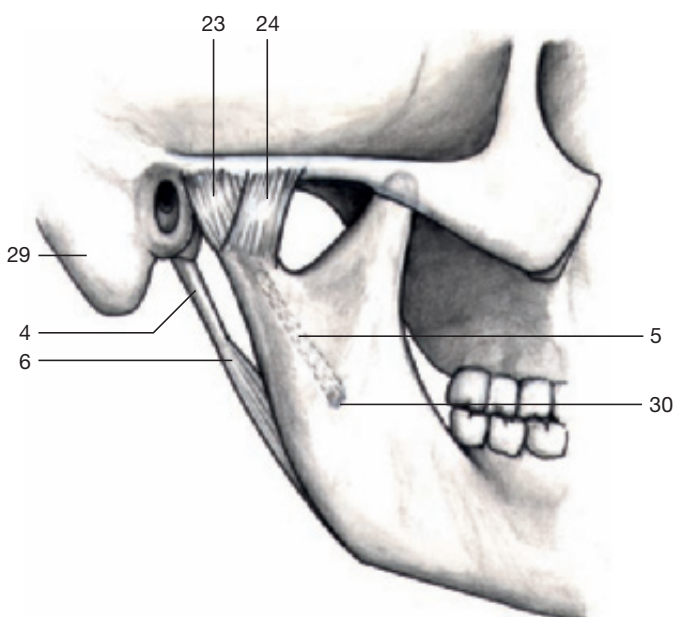


- 1 Groove for sigmoid sinus
- 2 Mandibular nerve
- 3 Lateral pterygoid muscle
- 4 Styloid process
- 5 Sphenomandibular ligament
- 6 Stylomandibular ligament
- 7 Mylohyoid groove
- 8 Ethmoidal air cells
- 9 Ethmoidal bulla
- 10 Hiatus semilunaris
- 11 Middle meatus
- 12 Inferior nasal concha
- 13 Limen nasi
- 14 Vestibule with hairs
- 15 Inferior meatus
- 16 Hard palate
- 17 Soft palate
- 18 Vestibule of oral cavity
- 19 Lower lip
- 20 Mandible
- 21 Zygomatic arch
- 22 External acoustic meatus
- 23 Articular capsule
- 24 Lateral ligament
- 25 Mandibular notch
- 26 Zygomatic bone
- 27 Coronoid process
- 28 Maxilla
- 29 Mastoid process
- 30 Mandibular foramen

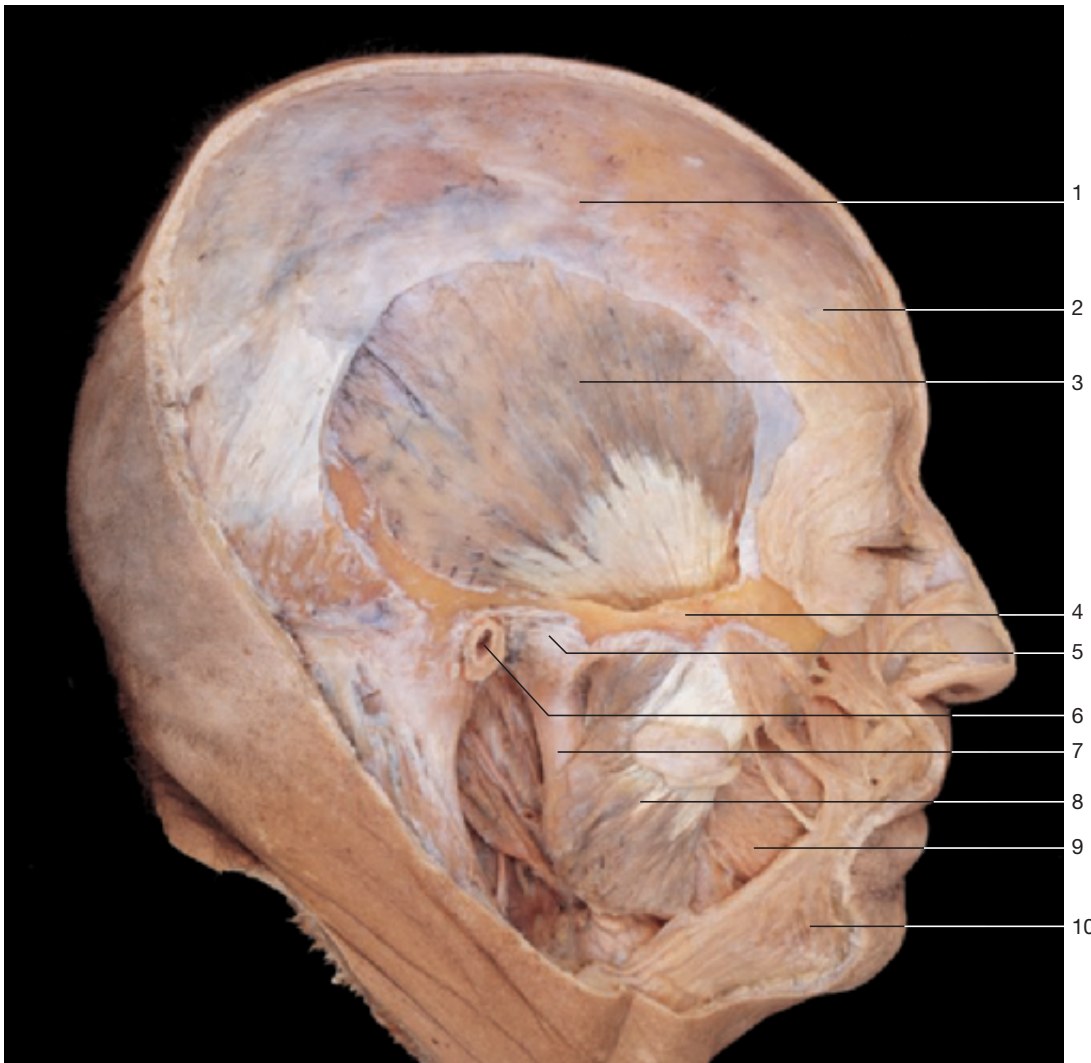
Ligaments of temporomandibular joint. Left half of the head (medial aspect).



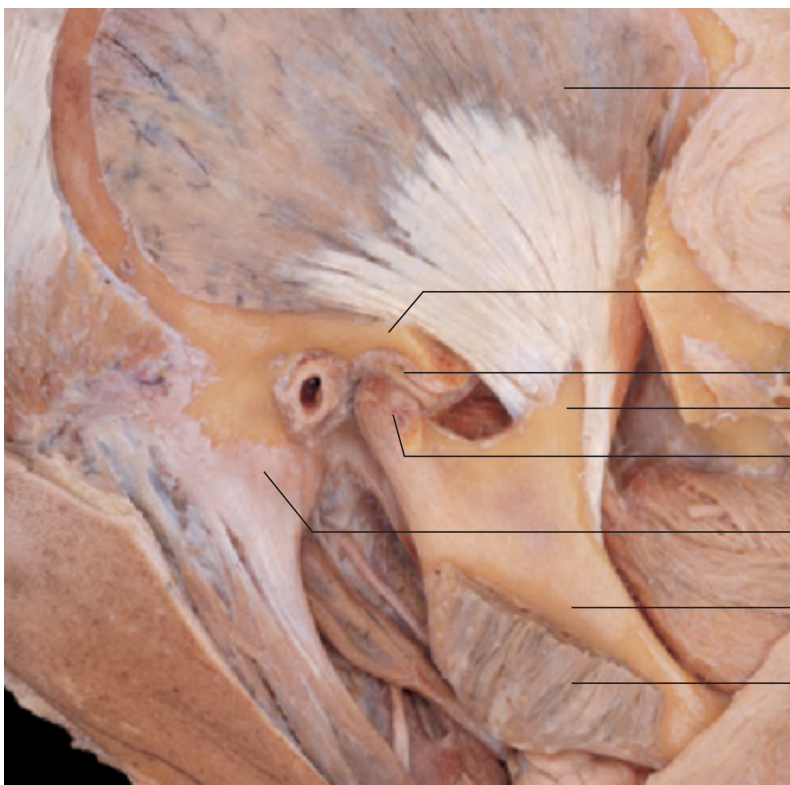
Temporomandibular joint with ligaments (lateral aspect).



Ligaments of temporomandibular joint (lateral aspect).

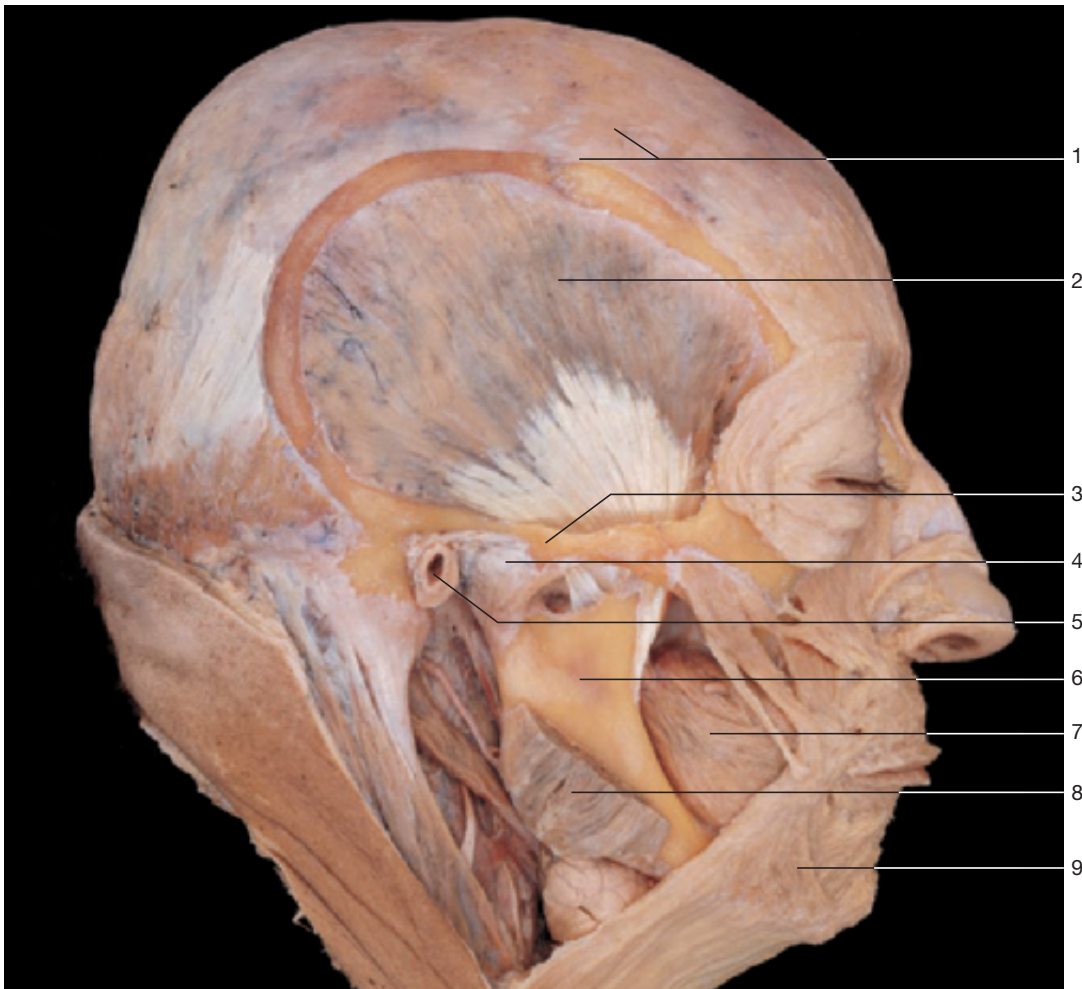

Temporomandibular joint and masticatory muscles. The masseter and temporal muscles are shown.

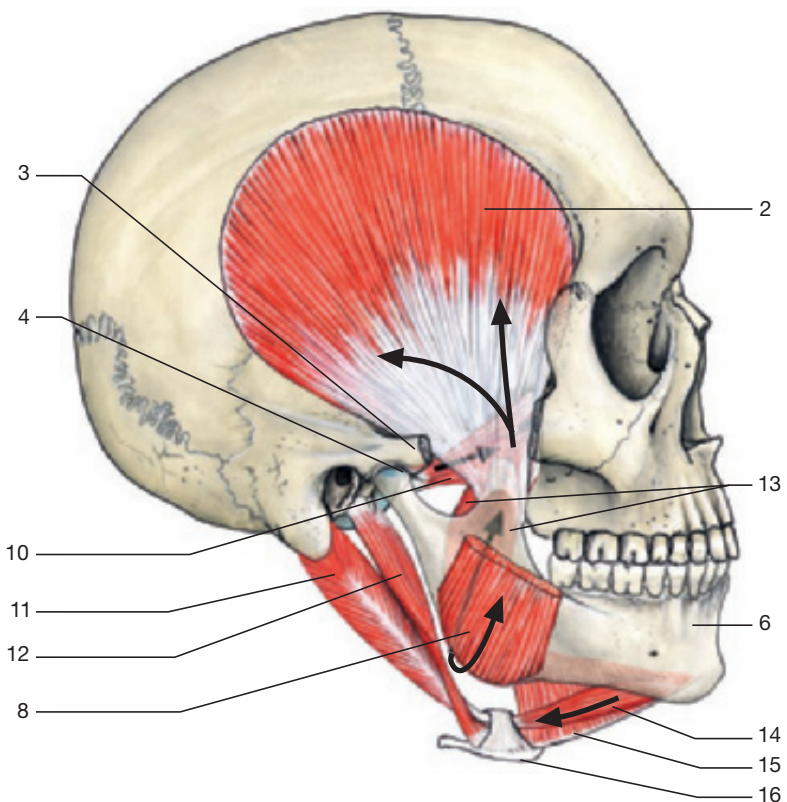


- 1 Galea aponeurotica
- 2 Frontal belly of occipitofrontalis muscle
- 3 Temporal muscle
- 4 Zygomatic arch
- 5 Temporomandibular joint
- 6 External acoustic meatus
- 7 Mandible
- 8 Masseter muscle
- 9 Buccinator muscle
- 10 Platysma muscle
- 11 Articular disc of temporomandibular joint
- 12 Coronoid process of mandible
- 13 Condylar process of mandible
- 14 Mastoid process

Temporal muscle with insertion at the mandible and the temporomandibular joint. Zygomatic arch and masseter muscle have been partly removed.



Temporomandibular joint and masticatory muscles. The masseter muscle has been partly removed.



- 1 Galea aponeurotica
- 2 Temporal muscle
- 3 Zygomatic arch
- 4 Temporomandibular joint
- 5 External acoustic meatus
- 6 Mandible
- 7 Buccinator muscle
- 8 Masseter muscle (cut)
- 9 Platysma muscle
- 10 Lateral pterygoid muscle
- 11 Posterior belly of digastric muscle
- 12 Stylohyoid muscle
- 13 Medial pterygoid muscle
- 14 Anterior belly of digastric muscle
- 15 Mylohyoid muscle
- 16 Hyoid bone

Effect of the masticatory muscles on the temporomandibular joint (arrows).