

Anatomy

A Photographic Atlas

Bearbeitet von
Johannes W. Rohen, Chihiro Yokochi, Elke Lütjen-Drecoll

8 2015. Taschenbuch. 560 S. Paperback
ISBN 978 3 7945 2982 7
Format (B x L): 21 x 29,7 cm
Gewicht: 2300 g

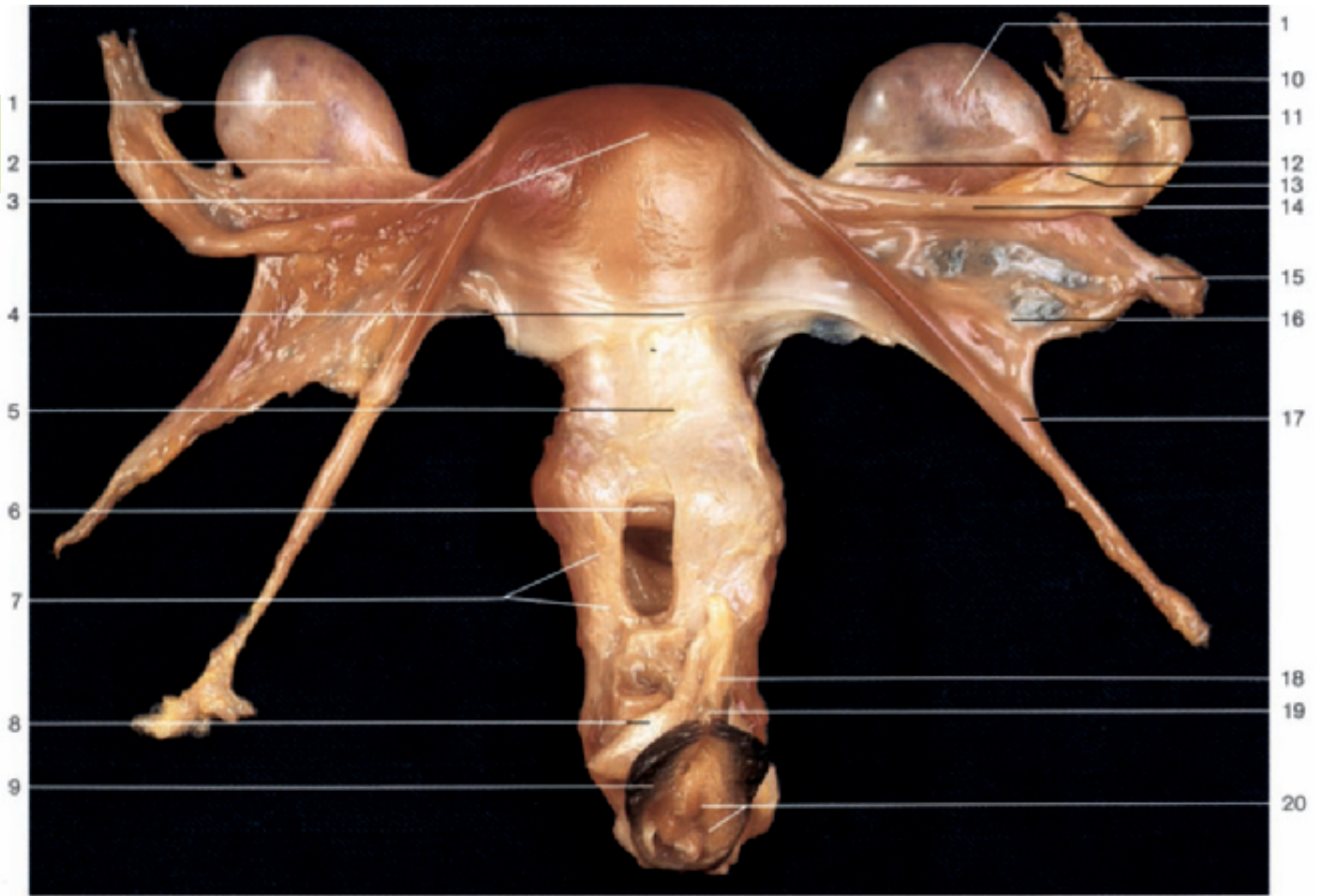
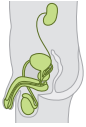[Weitere Fachgebiete > Medizin > Vorklinische Medizin: Grundlagenfächer > Anatomie](#)

Zu [Inhaltsverzeichnis](#)

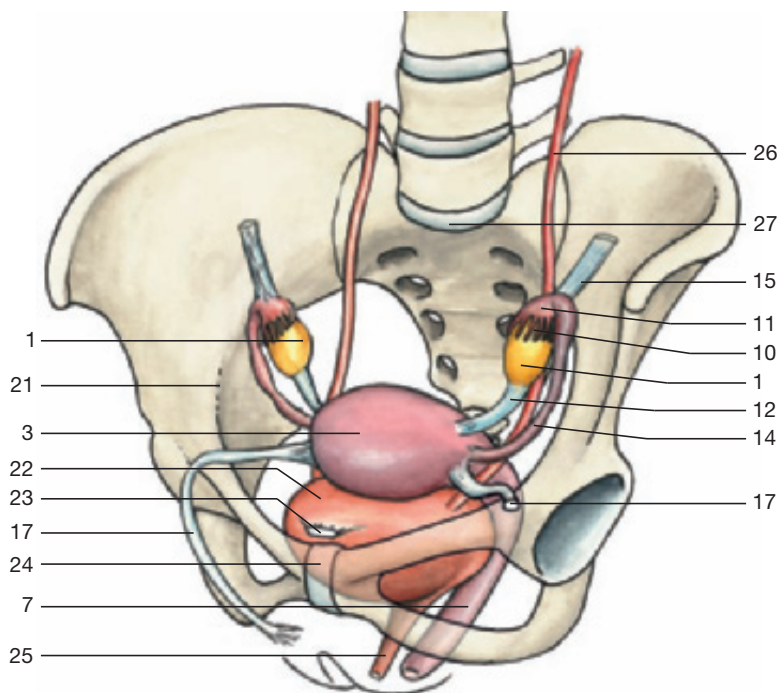
schnell und portofrei erhältlich bei


DIE FACHBUCHHANDLUNG

Die Online-Fachbuchhandlung beck-shop.de ist spezialisiert auf Fachbücher, insbesondere Recht, Steuern und Wirtschaft. Im Sortiment finden Sie alle Medien (Bücher, Zeitschriften, CDs, eBooks, etc.) aller Verlage. Ergänzt wird das Programm durch Services wie Neuerscheinungsdienst oder Zusammenstellungen von Büchern zu Sonderpreisen. Der Shop führt mehr als 8 Millionen Produkte.

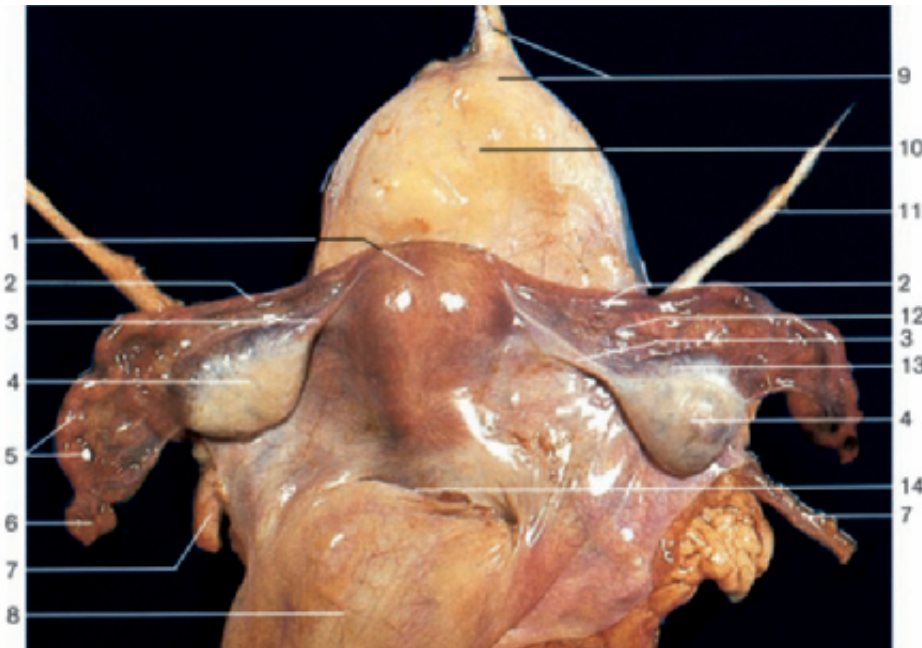
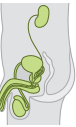

Female genital organs, isolated (anterior aspect). The anterior wall of the vagina has been opened to display the vaginal portion of the cervix.



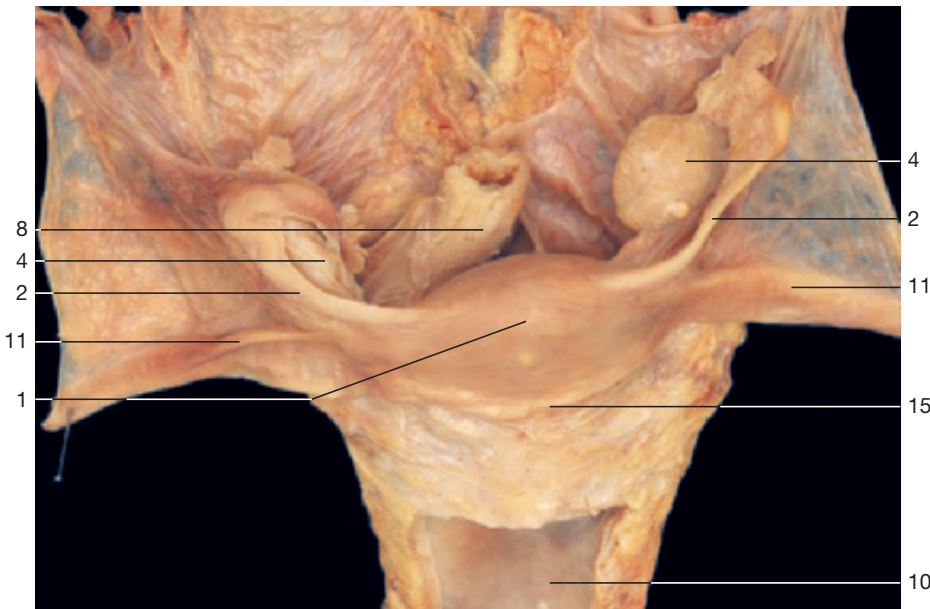
- 1 Ovary
- 2 Mesovarium
- 3 Fundus of uterus
- 4 Vesico-uterine pouch
- 5 Cervix of uterus
- 6 Vaginal portion of cervix
- 7 Vagina
- 8 Crus of clitoris
- 9 Labium minus
- 10 Fimbriae of uterine tube
- 11 Infundibulum of uterine tube
- 12 Ligament of the ovary
- 13 Mesosalpinx
- 14 Uterine tube
- 15 Suspensory ligament of ovary (caudally displaced)
- 16 Broad ligament of uterus
- 17 Round ligament of uterus
- 18 Corpus cavernosum of clitoris
- 19 Glans of clitoris
- 20 Hymen and vaginal orifice
- 21 Linea terminalis
- 22 Urinary bladder
- 23 Medial umbilical ligament
- 24 Pubic symphysis
- 25 Urethra
- 26 Ureter
- 27 Promontory

Position of female internal genital organs (oblique-anterior aspect).

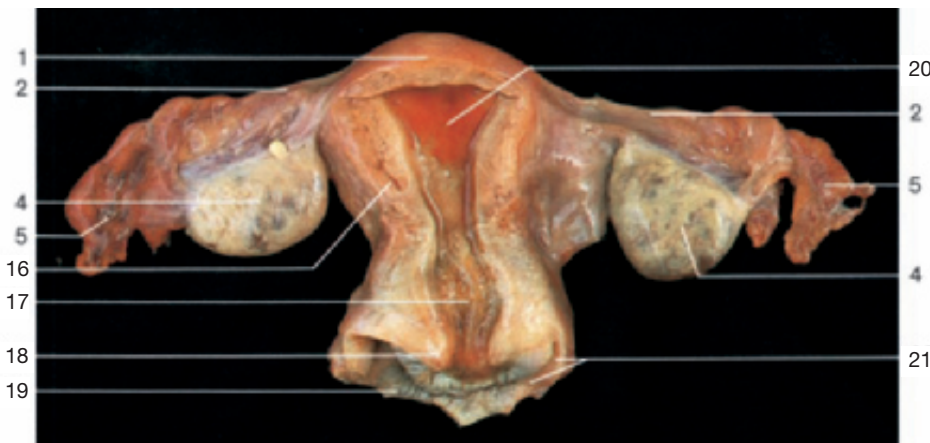

- 1 Fundus of uterus
- 2 Uterine tube
- 3 Ligament of the ovary
- 4 Ovary
- 5 Infundibulum of uterine tube
- 6 Fimbriae of uterine tube
- 7 Ureter
- 8 Rectum
- 9 Apex of urinary bladder and median umbilical ligament
- 10 Urinary bladder (fenestrated in the dissection in the middle)
- 11 Round ligament of uterus
- 12 Mesosalpinx
- 13 Mesovarium
- 14 Recto-uterine pouch (of Douglas)
- 15 Vesico-uterine pouch
- 16 Body of uterus
- 17 Cervix of uterus
- 18 Vaginal portion of cervix of uterus
- 19 Vagina
- 20 Mucous membrane of uterus congestion
- 21 Anterior fornix of vagina

Female genital organs, isolated (supero-posterior aspect).



Uterus and related organs, isolated (superior aspect). The left ovary is enlarged.



Uterus and related organs, isolated (posterior aspect). The posterior wall of the uterus has been opened.