

Anatomy

A Photographic Atlas

Bearbeitet von
Johannes W. Rohen, Chihiro Yokochi, Elke Lütjen-Drecoll

8 2015. Taschenbuch. 560 S. Paperback
ISBN 978 3 7945 2982 7
Format (B x L): 21 x 29,7 cm
Gewicht: 2300 g

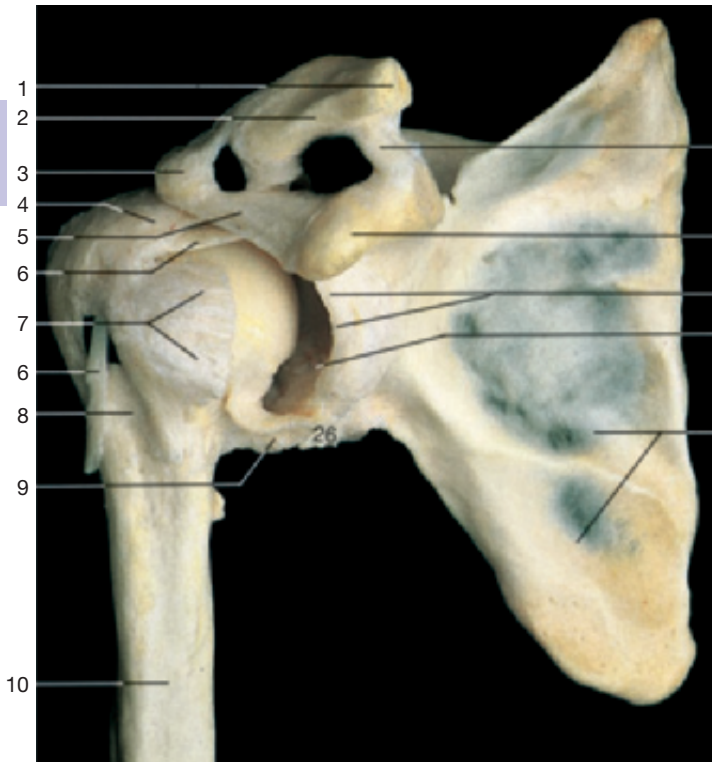
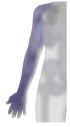[Weitere Fachgebiete > Medizin > Vorklinische Medizin: Grundlagenfächer > Anatomie](#)

Zu [Inhaltsverzeichnis](#)

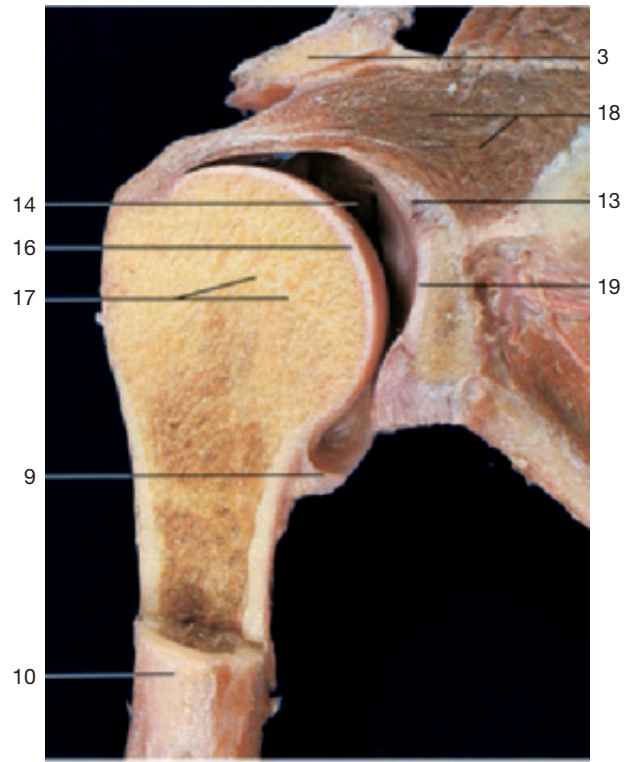
schnell und portofrei erhältlich bei

**beck-shop.de**
DIE FACHBUCHHANDLUNG

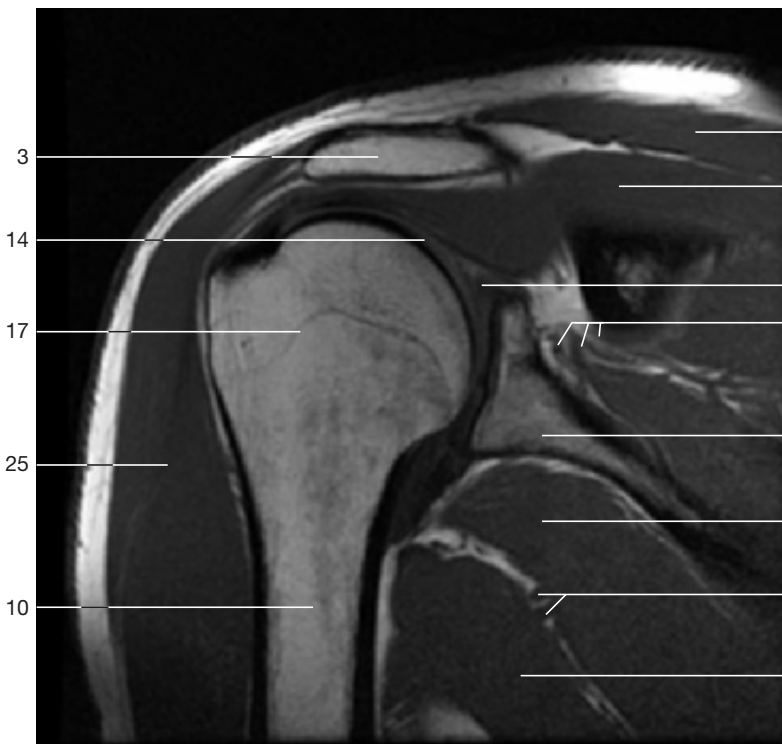
Die Online-Fachbuchhandlung [beck-shop.de](#) ist spezialisiert auf Fachbücher, insbesondere Recht, Steuern und Wirtschaft. Im Sortiment finden Sie alle Medien (Bücher, Zeitschriften, CDs, eBooks, etc.) aller Verlage. Ergänzt wird das Programm durch Services wie Neuerscheinungsdienst oder Zusammenstellungen von Büchern zu Sonderpreisen. Der Shop führt mehr als 8 Millionen Produkte.



Right shoulder joint. The anterior part of the articular capsule has been removed and the head of the humerus has been slightly rotated outward to show the cavity of the joint.

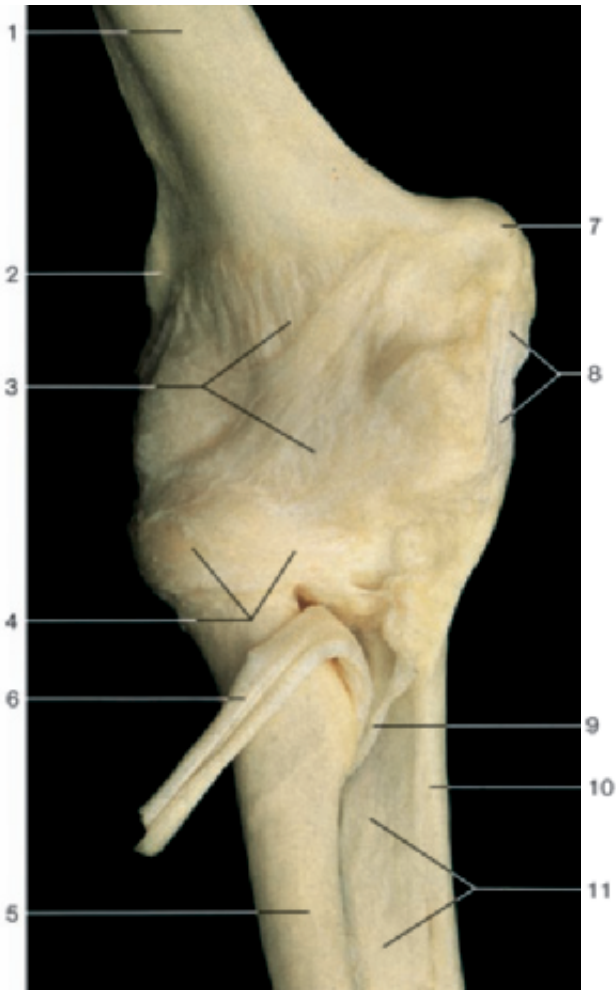


Coronal section through the right shoulder joint (anterior aspect).

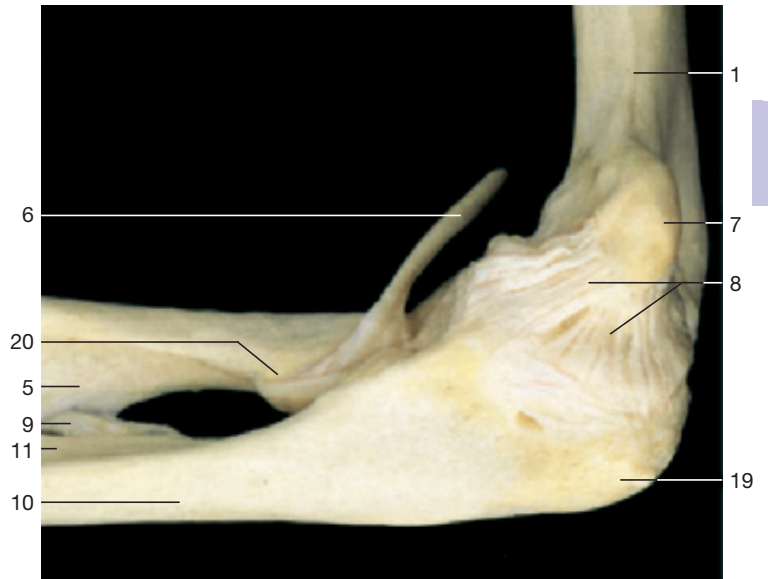


Coronal section through the right shoulder joint (MRI scan).
(Courtesy of Prof. Heuck, Munich, Germany.)

- 1 Acromial end of clavicle
- 2 Acromioclavicular joint
- 3 Acromion
- 4 Tendon of supraspinatus muscle (attached to the articular capsule)
- 5 Coraco-acromial ligament
- 6 Tendon of long head of biceps brachii muscle
- 7 Tendon of subscapularis muscle (attached to the articular capsule)
- 8 Intertubercular sulcus
- 9 Articular capsule of shoulder joint
- 10 Humerus
- 11 Trapezoid ligament
- 12 Coracoid process
- 13 Glenoid labrum
- 14 Shoulder joint (joint cavity)
- 15 Scapula
- 16 Head of humerus
- 17 Epiphysial line
- 18 Supraspinatus muscle
- 19 Glenoid cavity
- 20 Trapezius muscle
- 21 Suprascapular artery, vein, and nerve
- 22 Teres major muscle
- 23 Circumflexa scapular artery and vein
- 24 Latissimus dorsi muscle
- 25 Deltoid muscle
- 26 Tendon of long head of triceps brachii muscle

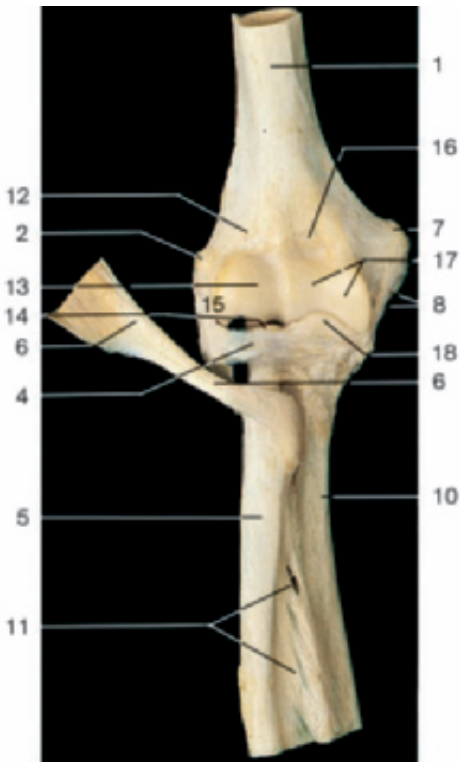


Ligaments of the elbow joint (anterior aspect).

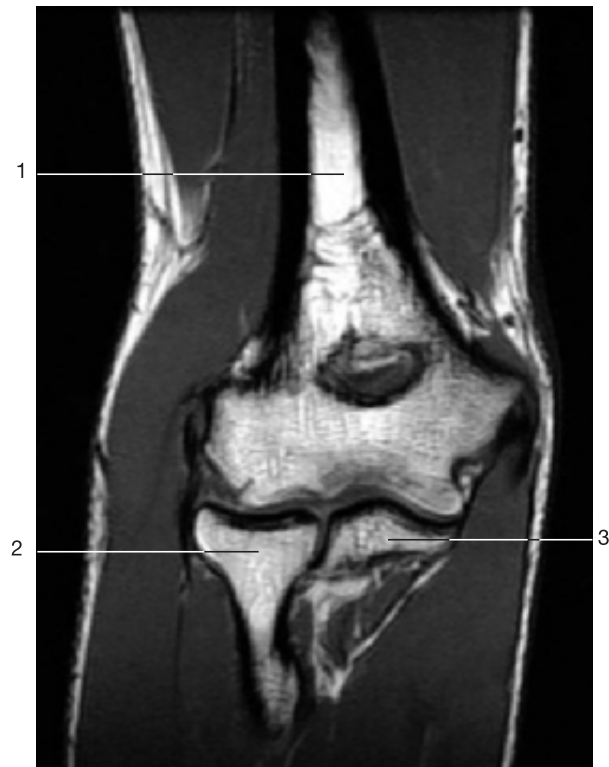

Ligaments of the elbow joint (medial aspect).

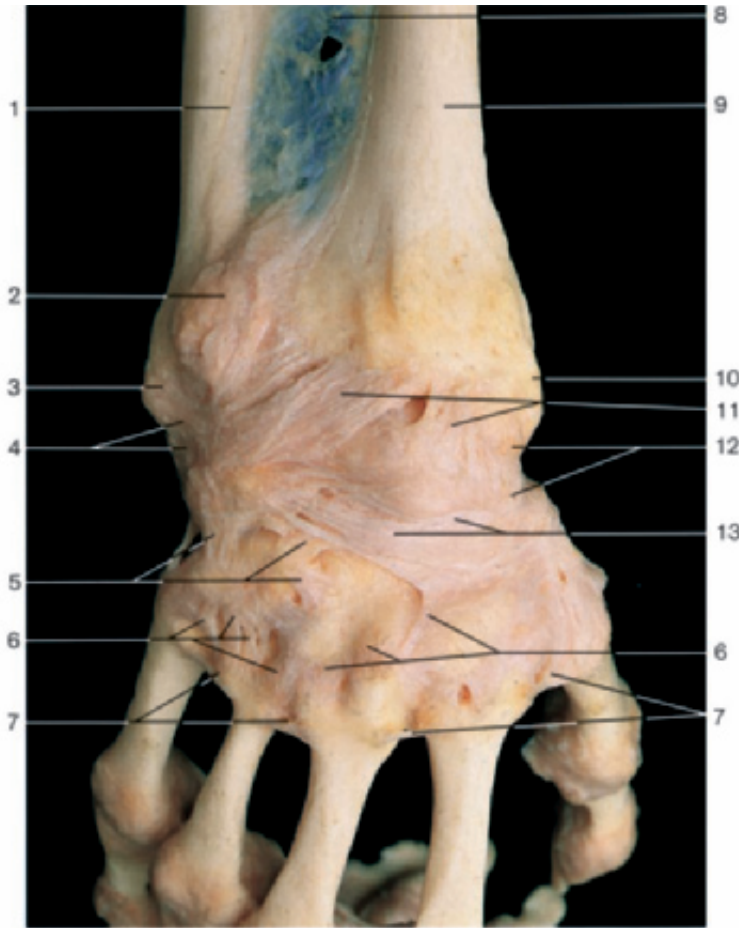
- | | |
|---|-------------------------------|
| 1 Humerus | 11 Interosseous membrane |
| 2 Lateral epicondyle of humerus | 12 Radial fossa |
| 3 Articular capsule | 13 Capitulum of humerus |
| 4 Anular ligament of proximal radio-ulnar joint | 14 Head of radius |
| 5 Radius | 15 Radial collateral ligament |
| 6 Tendon of biceps brachii muscle | 16 Coronoid fossa |
| 7 Medial epicondyle of humerus | 17 Trochlea of humerus |
| 8 Ulnar collateral ligament | 18 Coronoid process of ulna |
| 9 Oblique chord | 19 Olecranon |
| 10 Ulna | 20 Radial tuberosity |



Elbow joint with ligaments (anterior aspect). Articular capsule has been removed to show the anular ligament.

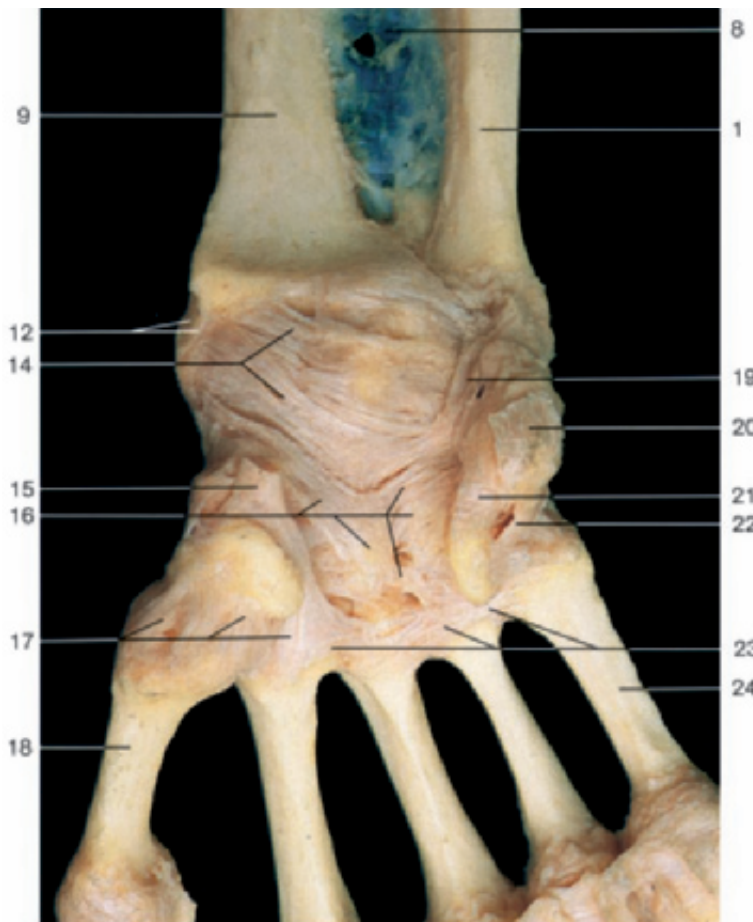


Coronal section through the elbow joint (MRI scan). (Courtesy of Prof. Heuck, Munich, Germany.)

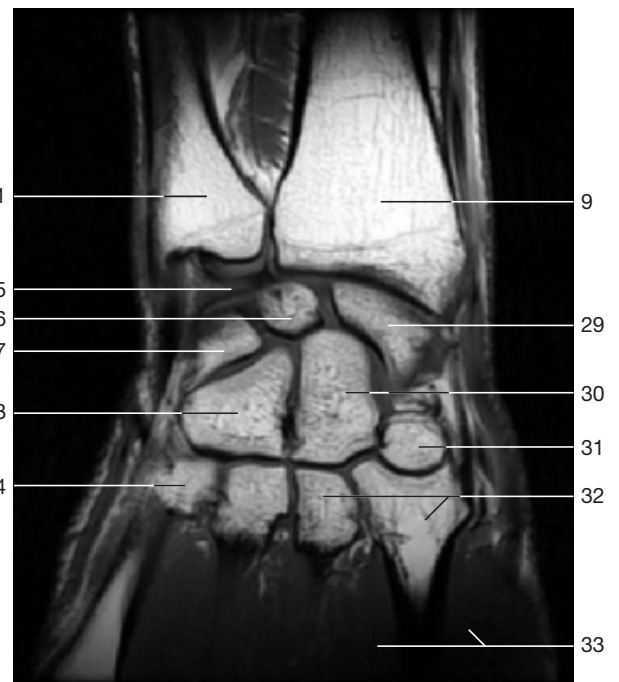


- 1 Ulna
- 2 Exostosis (pathological)
- 3 Head of ulna
- 4 Ulnar carpal collateral ligament
- 5 Deep intercarpal ligaments
- 6 Dorsal carpometacarpal ligaments
- 7 Dorsal metacarpal ligaments
- 8 Interosseous membrane
- 9 Radius
- 10 Styloid process of radius
- 11 Dorsal radiocarpal ligament
- 12 Radial collateral ligament
- 13 Articular capsule and dorsal intercarpal ligaments
- 14 Palmar radiocarpal ligament
- 15 Tendon of flexor carpi radialis muscle (cut)
- 16 Radiating carpal ligament
- 17 Palmar carpometacarpal ligaments
- 18 First metacarpal bone
- 19 Palmar ulnocarpal ligament
- 20 Tendon of flexor carpi ulnaris muscle (cut)
- 21 Pisohamate ligament
- 22 Pisometacarpal ligament
- 23 Palmar metacarpal ligaments
- 24 Fifth metacarpal bone
- 25 Articular disc (ulnocarpal)
- 26 Lunate bone
- 27 Triquetral bone
- 28 Hamate bone
- 29 Scaphoid (navicular) bone
- 30 Capitate bone
- 31 Trapezoid bone
- 32 Second and third metacarpal bones
- 33 Dorsal interossei muscles

Ligaments of hand and wrist (dorsal aspect).



Ligaments of hand and wrist (palmar aspect).



Coronal section through the hand and wrist (MRI scan). (Courtesy of Prof. Heuck, Munich, Germany.) Note the location of the wrist joint.