

# Anatomy

A Photographic Atlas

Bearbeitet von  
Johannes W. Rohen, Chihiro Yokochi, Elke Lütjen-Drecoll

8 2015. Taschenbuch. 560 S. Paperback  
ISBN 978 3 7945 2982 7  
Format (B x L): 21 x 29,7 cm  
Gewicht: 2300 g

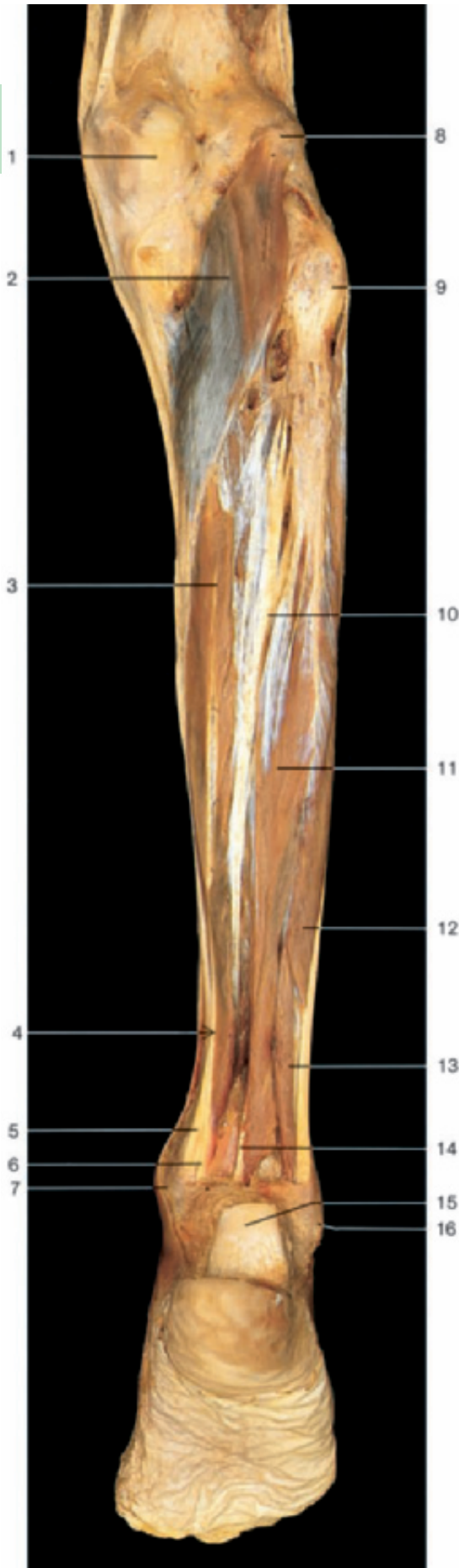
[Weitere Fachgebiete > Medizin > Vorklinische Medizin: Grundlagenfächer > Anatomie](#)

Zu [Inhaltsverzeichnis](#)

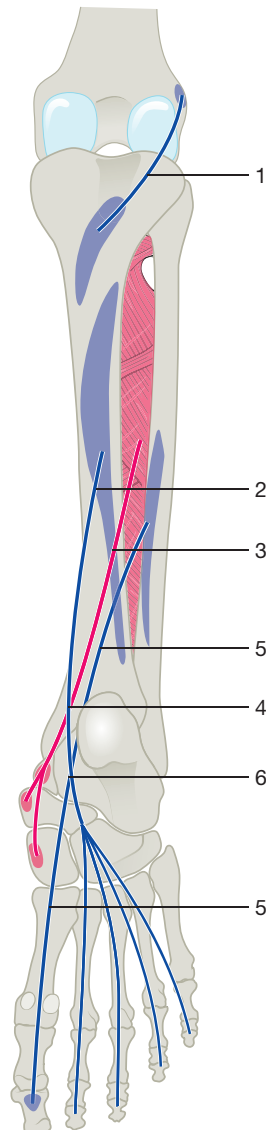
schnell und portofrei erhältlich bei

  
DIE FACHBUCHHANDLUNG

Die Online-Fachbuchhandlung [beck-shop.de](#) ist spezialisiert auf Fachbücher, insbesondere Recht, Steuern und Wirtschaft. Im Sortiment finden Sie alle Medien (Bücher, Zeitschriften, CDs, eBooks, etc.) aller Verlage. Ergänzt wird das Programm durch Services wie Neuerscheinungsdienst oder Zusammenstellungen von Büchern zu Sonderpreisen. Der Shop führt mehr als 8 Millionen Produkte.



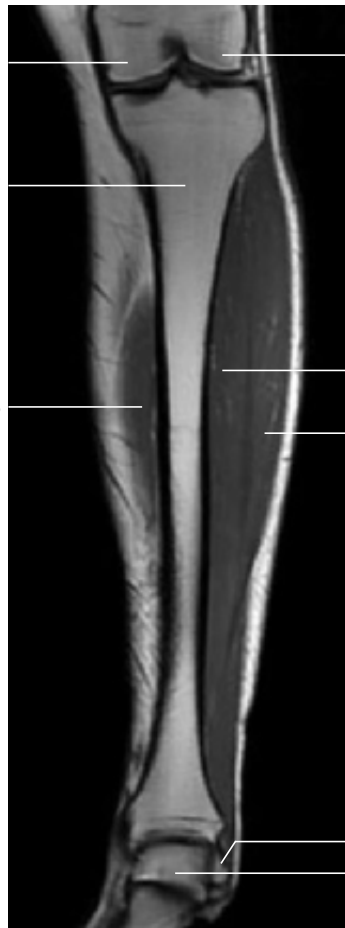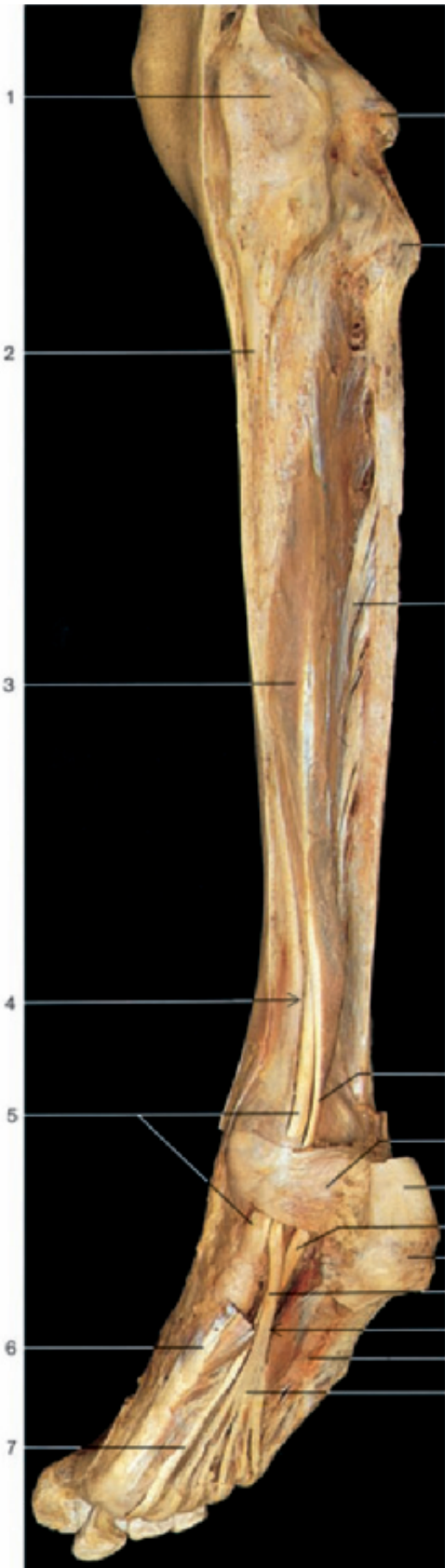- 1 Medial condyle of femur
- 2 Popliteus muscle
- 3 Flexor digitorum longus muscle
- 4 Crossing of tendons in the leg
- 5 Tendon of tibialis posterior muscle
- 6 Tendon of flexor digitorum longus muscle
- 7 Medial malleolus
- 8 Lateral condyle of femur
- 9 Head of fibula
- 10 Tibialis posterior muscle
- 11 Flexor hallucis longus muscle
- 12 Peroneus longus muscle
- 13 Peroneus brevis muscle
- 14 Tendon of flexor hallucis longus muscle
- 15 Calcaneal or Achilles tendon (divided)
- 16 Lateral malleolus



- 1 Popliteus muscle (blue)
- 2 Flexor digitorum longus muscle (blue)
- 3 Tibialis posterior muscle (red)
- 4 Crossing of tendons in the leg
- 5 Flexor hallucis longus muscle (blue)
- 6 Crossing of tendons in the sole

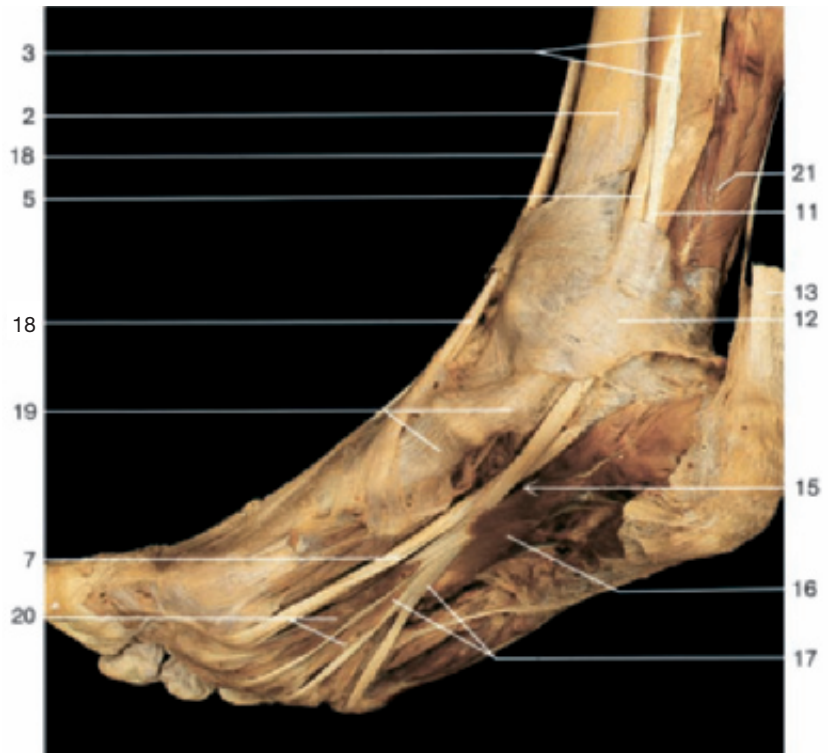Deep flexor muscles of leg and foot  
(right side, posterior aspect).

Course of the deep flexor muscles of the leg (posterior aspect).



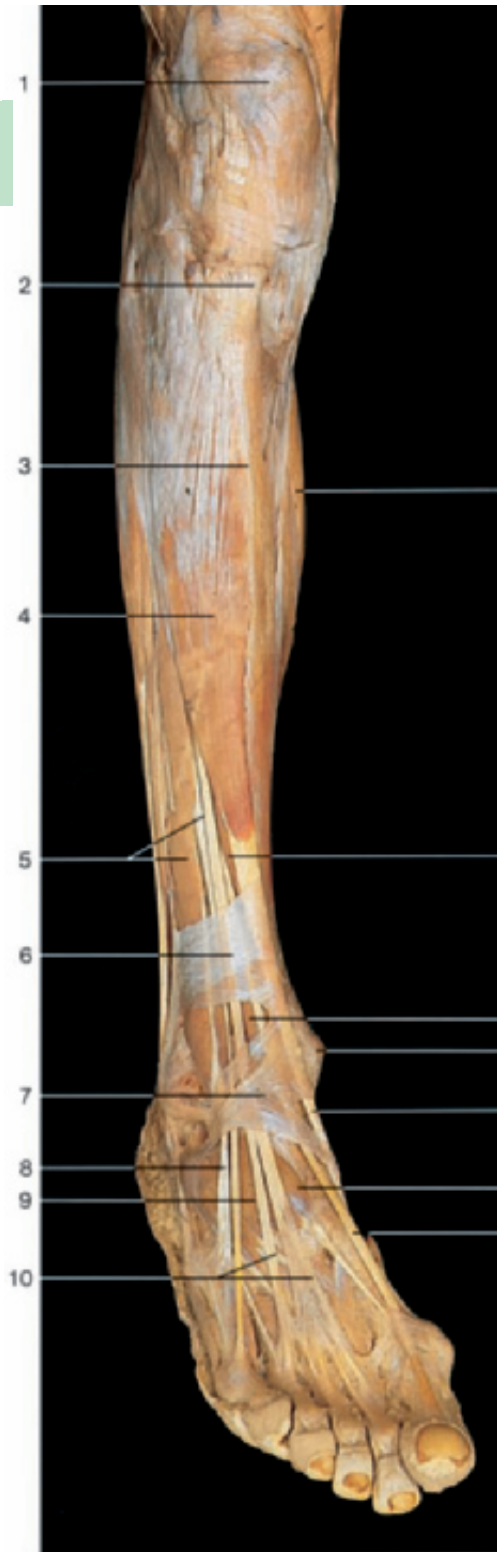- 1 Medial condyle of femur
- 2 Tibia
- 3 Flexor digitorum longus muscle
- 4 Crossing of tendons in the leg
- 5 Tendon of tibialis posterior muscle
- 6 Abductor hallucis muscle
- 7 Tendon of flexor hallucis longus muscle
- 8 Lateral condyle of femur
- 9 Head of fibula
- 10 Tibialis posterior muscle
- 11 Tendon of flexor digitorum longus muscle
- 12 Flexor retinaculum
- 13 Calcaneal or Achilles tendon
- 14 Calcaneal tuberosity
- 15 Crossing of tendons in the sole
- 16 Quadratus plantae muscle
- 17 Tendons of flexor digitorum longus muscle
- 18 Tendon of tibialis anterior muscle
- 19 Area of insertion of tibialis posterior muscle
- 20 Lumbrical muscles
- 21 Flexor hallucis longus muscle
- 22 Tibialis anterior muscle
- 23 Extensor hallucis longus muscle
- 24 Lateral malleolus of fibula
- 25 Trochlea of talus

Coronal section through the leg (MRI scan). (From Heuck et al., MRT-Atlas, 2009.)

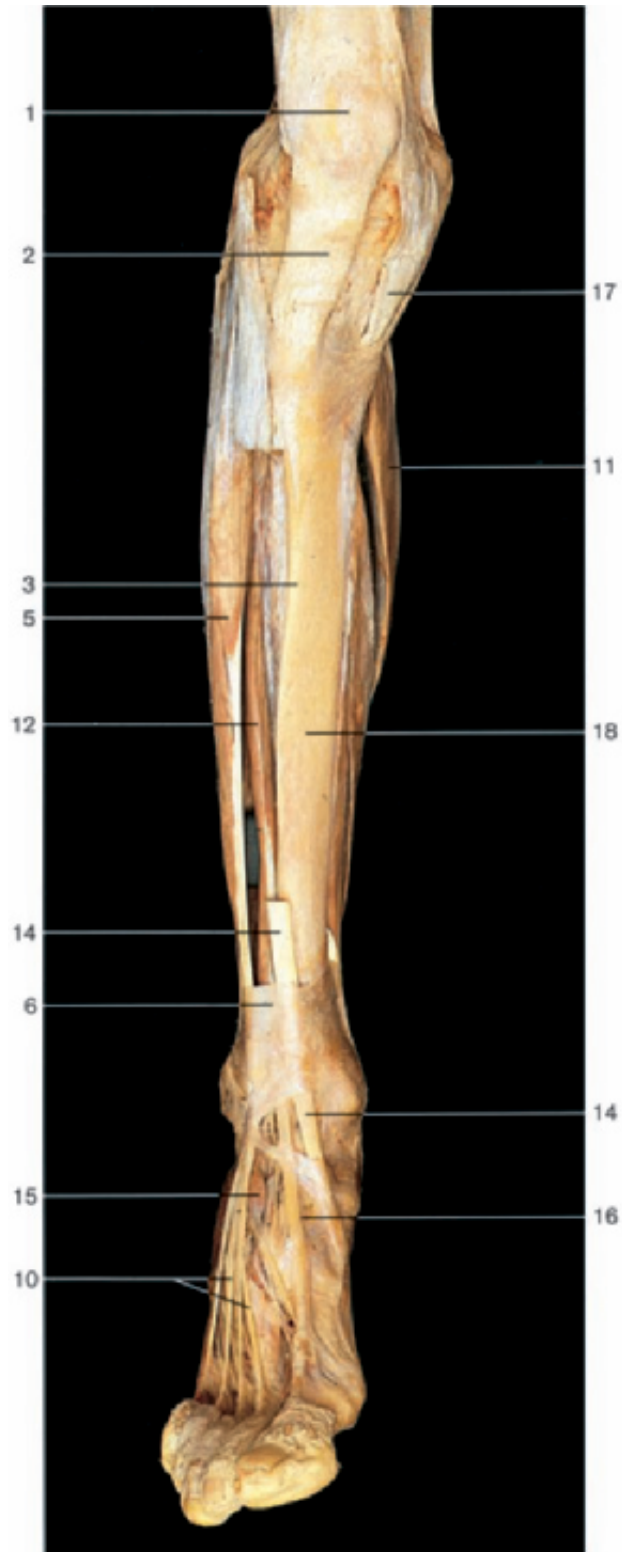


Sole of the right foot with tendons of long flexor muscles (oblique-medial and inferior aspect).

Deep flexor muscles of leg and foot (right side, posterior oblique-medial aspect). Flexor digitorum brevis and flexor hallucis longus muscles have been removed.



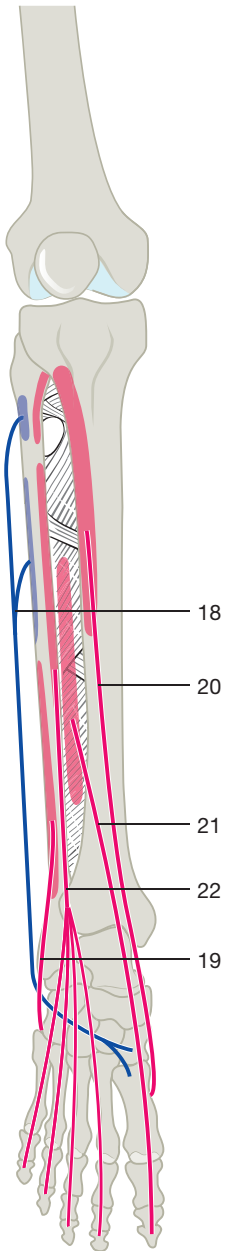
Extensor muscles of leg and foot (right side, oblique antero-lateral aspect).



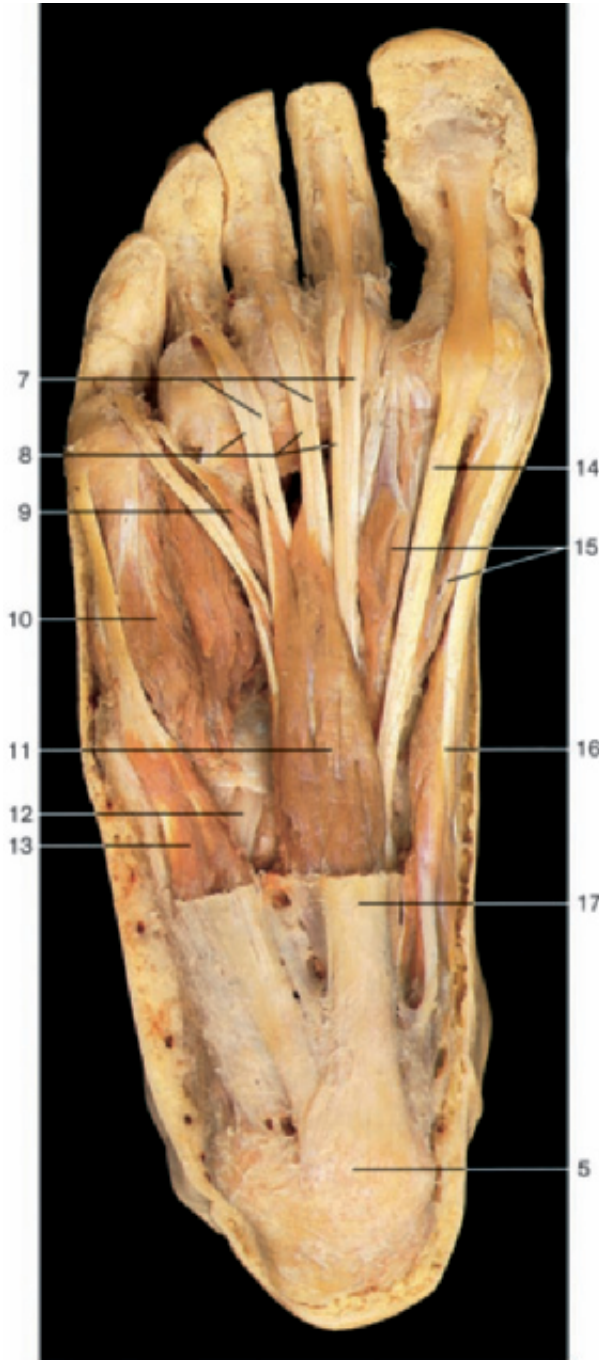
Extensor muscles of leg and foot (right side, anterior aspect). Part of the tibialis anterior muscle has been removed.

- |                                    |  |   |
|------------------------------------|--|---|
| 1 Patella                          | 8 Tendon of peroneus tertius muscle            | 14 Tendon of tibialis anterior muscle   |
| 2 Patellar ligament                | 9 Extensor digitorum brevis muscle             | 15 Extensor hallucis brevis muscle  |
| 3 Anterior margin of tibia         | 10 Tendons of extensor digitorum longus muscle | 16 Tendon of extensor hallucis longus muscle  |
| 4 Tibialis anterior muscle         | 11 Soleus muscle                               | 17 Common tendon of gracilis, semitendinosus, and sartorius muscles (pes anserinus) |
| 5 Extensor digitorum longus muscle | 12 Extensor hallucis longus muscle             | 18 Tibia  |
| 6 Superior extensor retinaculum    | 13 Medial malleolus                            |   |
| 7 Inferior extensor retinaculum    |  |   |

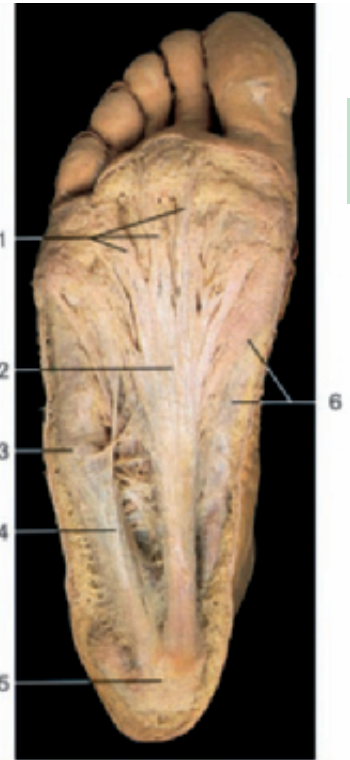



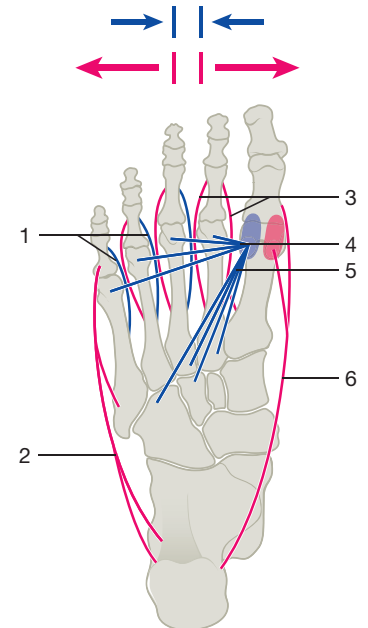
Course of the extensor muscles of the leg (anterior aspect).



Muscles of the sole of foot, superficial layer. The plantar aponeurosis and the fasciae of the superficial muscles have been removed.



Sole of the foot with the plantar aponeurosis.



Course of abductor and adductor muscles of the foot (plantar aspect). Red arrows: abduction; blue arrows: adduction.

- |   |  |
|---|--|
| 1 Longitudinal bands of plantar aponeurosis       | 12 Tendon of peroneus longus muscle        |
| 2 Plantar aponeurosis                             | 13 Abductor digiti minimi muscle           |
| 3 Position of tuberosity of fifth metatarsal bone | 14 Tendon of flexor hallucis longus muscle |
| 4 Muscles of fifth toe with fascia                | 15 Flexor hallucis brevis muscle           |
| 5 Calcaneal tuberosity                            | 16 Abductor hallucis muscle                |
| 6 Muscles of great toe with fascia                | 17 Plantar aponeurosis (cut)               |
| 7 Tendons of flexor digitorum longus muscle       | 18 Peroneus longus muscle                  |
| 8 Tendons of flexor digitorum brevis muscle       | 19 Peroneus brevis muscle                  |
| 9 Lumbrical muscle                                | 20 Tibialis anterior muscle                |
| 10 Flexor digiti minimi brevis muscle             | 21 Extensor hallucis longus muscle         |
| 11 Flexor digitorum brevis muscle                 | 22 Extensor digitorum longus muscle        |

- |  |
|--|
| 1 Plantar interossei muscles (blue)                  |
| 2 Abductor digiti minimi muscle (red)                |
| 3 Dorsal interossei muscles (red)                    |
| 4 Transverse head of adductor hallucis muscle (blue) |
| 5 Oblique head of adductor hallucis muscle (blue)    |
| 6 Abductor hallucis muscle (red)                     |